

Avoiding Flexor Tendon Repair Rupture with Intraoperative Total Active Movement Examination

Amanda Higgins, B.Sc.O.T.

Donald H. Lalonde, M.D.

Michael Bell, M.D.

Daniel McKee, B.Sc.

Jan F. Lalonde, R.N.,

C.P.S.N.

*Saint John, New Brunswick, and
Ottawa, Ontario, Canada*

Background: Wide-awake flexor tendon repair in tourniquet-free unsedated patients permits intraoperative Total Active Movement examination (iTAME) of the freshly repaired flexor tendon. This technique has permitted the intraoperative observation of tendon repair gapping induced by active movement when the core suture is tied too loosely. The gap can be repaired intraoperatively to decrease postoperative tendon repair rupture rates. The authors record their rupture rate in the first 15 years of experience with iTAME.

Methods: This was a retrospective chart review of 102 consecutive patients with wide-awake flexor tendon repair (no tourniquet, no sedation, and pure locally injected lidocaine with epinephrine anesthesia) in which iTAME was performed by two hand surgeons in two Canadian cities between 1998 and 2008. Intraoperative gapping and postoperative rupture were analyzed.

Results: The authors observed intraoperative bunching and gap formation with active movement in flexor tendon repair testing (iTAME) in seven patients. In all seven cases, they redid the repair and repeated iTAME to confirm gapping was eliminated before closing the skin, and those seven patients did not rupture postoperatively. In 68 patients with known outcomes, four of 122 tendons ruptured (tendon rupture rate, 3.3 percent) in three of 68 patients (patient rupture rate, 4.4 percent). All three patients who ruptured had accidental jerk forced rupture. All those patients who did what we asked them did not rupture.

Conclusions: Tendons can gap with active movement if the core suture is tied too loosely. Gapping can be recognized intraoperatively with iTAME and repaired to decrease postoperative rupture. (*Plast. Reconstr. Surg.* 126: 941, 2010.)

We perform the vast majority of our flexor tendon repairs under pure local anesthesia in nonsedated patients with no tourniquet using only lidocaine and epinephrine for anesthesia and hemostasis. This wide-awake approach^{1,2} allows our comfortable, nonsedated, cooperative, tourniquet-free patients to test the freshly repaired tendon with full active flexion and extension before we close the skin in every case. The term that describes this maneuver is intraoperative Total Active Movement examination (iTAME).

We have a combined 15 years of experience with iTAME. With this iTAME, we have seen the suture bunch in the tendon and create a gap in the repair in seven patients, where the core sutures were initially tied too loosely. On those occasions, we have repaired the gap intraoperatively and the patients did not rupture postoperatively. We feel that the same suture bunching would have occurred postoperatively and would have led to rupture if we had not recognized it and repaired it intraoperatively.

We have had the impression that eliminating the active movement/tendon bunching source of

From Saint John Regional Hospital, Dalhousie University, and Ottawa University.

Received for publication January 10, 2010; accepted February 23, 2010.

Presented at the 2010 Annual Meeting of the American Association for Hand Surgery, in Boca Raton, Florida, January 6 through 11, 2010.

Copyright ©2010 by the American Society of Plastic Surgeons

DOI: 10.1097/PRS.0b013e3181e60489

Disclosures: Dr. Lalonde is a consultant for ASSI instruments, which has no bearing on the contents of this article. None of the other authors has any financial disclosures to report.

tendon repair gapping has decreased our flexor tendon repair rupture rate. We therefore decided to document the incidence of rupture in our first combined 15 years of experience of consecutive iTAME wide-awake flexor tendon repairs.

PATIENTS AND METHODS

A retrospective chart review was performed of every consecutive wide-awake flexor tendon repair (no tourniquet, no sedation, and pure locally injected lidocaine with epinephrine anesthesia) in which iTAME was performed by two hand surgeons in two Canadian cities (Saint John and Ottawa) between 1998 and 2008. A total of 102 patients were studied (28 patients with 45 tendons from Saint John and 74 patients with 128 tendons from Ottawa), comprising a total of 173 flexor tendon repairs.

There were 25 flexor pollicis longus repairs: seven in zone 1, eight in zone 2, five in zone 3, three in zone 4, and two in undocumented zones. There were 148 flexor digitorum profundus and flexor digitorum superficialis repairs: 61 in zone 1, 57 in zone 2, 19 in zone 3, five in zone 4, and six in undocumented zones. All of these were complete repairs except for two of the tendons, which were partial repairs with 75 percent and 30 percent lacerations. There were 22 women and 87 men involved in this study.

Only flexor tendon injuries that were repaired using local anesthesia and epinephrine in which iTAME was performed were included in the study. Patients with digital nerve repair were included. The repairs consisted of mostly two-strand with some four-strand Kessler repairs with monofilament or braided nonabsorbable suture. Epitenon sutures were used under pulleys.

Postoperative Follow-Up

Surgeon and therapist charts were reviewed for 102 patients to determine length and adequacy of patient follow-up. Records were checked to see whether patients were followed by either surgeon or therapist for 12 weeks after surgery. Patients who could not be physically examined during the entire 12-week therapy program were followed up by telephone interview. Patients were asked whether they were able to bend the injured finger or thumb at both the middle and end joints, whether their end joint of the finger or thumb felt floppy or straight when the middle joint was bent, and whether they felt their finger was moving since having the surgery. If the answers did not clearly confirm an intact tendon repair, the patient was

reported as one of the unknown rupture patients. If patients were not physically examined up to 12 weeks, and if they could not be satisfactorily followed by telephone, they were considered to have an unknown rupture rate because of insufficient follow-up.

RESULTS

Ottawa Patients

Of the 74 patients seen in Ottawa, 128 flexor tendons were repaired, with three repair ruptures recorded in two patients. One long finger flexor digitorum profundus (2001) ruptured 8 days after repair when the patient caught his baby falling in a baby seat getting out of the car. Re-repair was performed under local anesthesia with lidocaine and epinephrine and did not rupture with follow-up past 30 months after the second repair. The other patient (2005) had both small finger tendons rupture 2.2 months after repair in an accident at work in which the operated finger was reinjured when it was wedged between two heavy metal falling objects.

Forty-seven of the remaining 72 patients did not complete the entire 3-month flexor tendon program follow-up. These patients were therefore contacted by telephone to determine whether their repair had ruptured unbeknownst to the surgeon or therapist. We were able to satisfactorily contact 19 of these 43 patients who were all verbally able to report that their injured fingers were able to bend. This left 24 patients (43 tendons) with insufficient follow-up that could not be reported as rupture free. This brings the known flexor tendon repair number to 85, with a rupture rate of 3.5 percent of the tendons.

Saint John Patients

Of the 28 patients seen in Saint John, 45 flexor tendons were repaired, with one repair rupture recorded. The only tendon rupture was the flexor digitorum profundus of a small finger (2004) ruptured 10 days after repair as the patient punched someone while in jail.

There were 16 patients who did not complete the entire 3-month flexor tendon program follow-up. We were able to establish nonrupture in 11 of these 16 patients (19 tendons) by telephone. We were able to get two of these 11 patients to come back for a recheck by either the surgeon or the hand therapist, and it was determined that the tendons were not ruptured. This left five patients (eight tendons) that cannot be reported as being rupture free. This brings the known flexor tendon

repair number to 37, with a tendon rupture rate of 2.7 percent.

Combined Data

Of all 173 wide-awake flexor tendon repairs in 102 patients in which iTAMe was performed, 122 of these tendons in 68 patients have a known outcome. In the 68 patients with known outcomes, four of 122 flexor tendons repaired ruptured (tendon rupture rate, 3.3 percent) in three of 68 patients (patient rupture rate, 4.4 percent). All three patients had well-documented rupture events that were accidentally induced with violent jerk movement. There were no ruptures in patients who followed prescribed controlled postoperative therapy and use of the fingers. The last recorded rupture occurred in 2005 from charts reviewed from 1998 to 2008. The last 3 years had no ruptures.

DISCUSSION

The death of the myth of epinephrine danger in the finger in the past decade^{3,4} has permitted us to perform flexor tendon repairs on wide-awake comfortable patients with no tourniquet, as if they were at the dentist. During surgery, these non-sedated cooperative patients are able to totally actively flex and extend their fingers while the surgeon examines the tendon repair site so that adjustments can be made before the skin is closed (iTAMe). The authors report their first 15 years of experience of tendon rupture after wide-awake flexor tendon repair and iTAMe. Only three patients ruptured. All three patients had well-documented rupture events that were accidentally induced postoperatively with violent jerk movement. All those patients who did what we asked them after surgery did not rupture, and the authors did not have any ruptures in the last 3 years of the study.

Until now, the causes of tendon rupture have usually been listed as poor surgical technique, infection, inadequate suture material, overly aggressive therapy, patient noncompliance, and tendon “softening” that peaks in the 2 weeks after surgery.⁵ The authors of this article would like to add to the literature another cause of tendon rupture: tendon bunching in the suture resulting from the forces of active flexion on a tendon repaired with the core sutures being too loose. In this report, the authors document the observation of flexor tendon repair gap occur with iTAMe. (Click the link <http://links.lww.com/A657> to view the film from the Video Plus article on wide-awake flexor tendon repair¹ and go to the 18-minute

24-second mark of the film to see tendon bunching causing a gap in a flexor tendon repair.) When core sutures are not tied tightly enough, the tendon bunches in the suture and gaps with active movement. The authors have seen it intraoperatively in seven patients. One of those seven cases can be seen in the film linked above. In all seven cases, they redid the repair and repeated the iTAMe to confirm that gapping was eliminated before closing the skin, and those seven patients did not rupture postoperatively. The authors believe that if they had performed the operation under general or block anesthesia where iTAMe is not possible, the tendon bunching may well have occurred when the patients had started their active movement in the postoperative period, and this may have led to postoperative rupture.

Both of the tendons illustrated in Figures 1 and 2 have been repaired with core sutures that are too loose and would likely gap and rupture with suture bunching in the postoperative period. The tendon in Figure 1 has the skin closed and leaves the core sutures too loose, whereas the tendon in Figure 2 had iTAMe, which permitted recognition of the gapping that can be repaired before the skin is closed (Table 1).

The most dreaded complication of flexor tendon repair is rupture. The outcome of this terrible complication is seldom satisfactory. It is therefore important to do anything we can to avoid or decrease the rate of this complication. Most of the world literature on flexor tendon repair rupture is focused on animal models,⁶ with little human literature except for the reporting of rupture rates. Tang⁷ reported that tendon repair ruptures occur

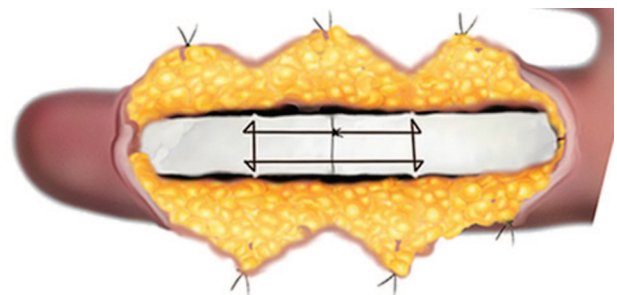


Fig. 1. This tendon has just been repaired with a core suture that is too loose. It looks okay but it is not. There is no gap seen at this time because it has not been tested with iTAMe. This is how many repairs are accepted and the skin closed under general or block anesthesia, as they are not tested for active movement intraoperatively. This repair may well rupture in the postoperative period when the tendon bunches in the suture when active movement begins.

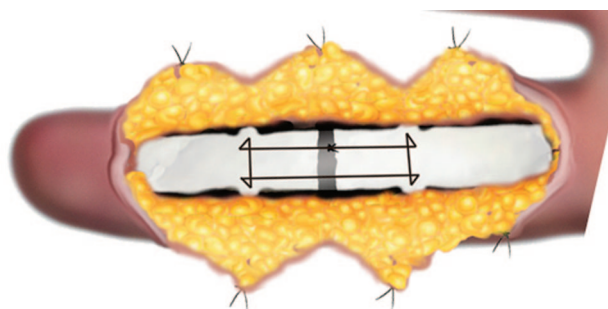


Fig. 2. This tendon has also just been repaired with a core suture that is too loose. This too loosely repaired tendon has been tested with iTAMe of the freshly repaired flexor tendon during wide-awake flexor tendon repair. Tendon bunching in the suture has occurred and a gap has revealed itself. The gap can be corrected before the skin is closed and repeated iTAMe will verify that the suture is now snug enough to withstand the forces of active flexion. It is better to discover that a core suture is too loose *during* the operation when it can be redone than *after* the operation when a postoperative rupture occurs.

in 4 to 10 percent of repaired fingers and 3 to 17 percent in flexor pollicis longus of thumbs. Peck et al.⁸ reported rupture rates of 4 to 17 percent. Boyer et al.⁹ commented that a 9 percent rupture rate is considered a high repair-site failure and should be taken into consideration when using a certain postoperative program. Harris et al.¹⁰ reported a low rupture rate of 4 percent in 526 fingers. Until now, all articles in the literature dealing with flexor tendon repair rupture have one thing in common: all tendon repairs occurred under general or proximal block (Bier or axillary) anesthesia. None of those patients tested the repair during the operation (iTAMe) to reveal and correct suture bunching to prevent postoperative rupture.

Two of the clear weaknesses of our study are its retrospective design and the fact that some of the follow-up data were obtained by telephone for part of the postoperative period. Postoperative follow-up is a challenge in all flexor tendon repair studies, as many of the patients who put themselves in a situation where tendons get lacerated are not always reliable. We only included telephone follow-up where we felt confident that a lack of rupture could be determined on the call.

The ideal way to study whether or not wide-awake flexor tendon repair and iTAMe reduce tendon rupture rates would be to test these patients and compare them prospectively in a randomized level I study to a group of patients who are asleep or sedated with blocks and in whom the repairs cannot be actively tested during surgery. The authors encourage those who still use general or block anesthesia to perform such a study.

Table 1. Case Breakdown

	Ottawa	Saint John	Total
No. of patients with tendon repairs	74	28	102
No. of patients with adequate follow-up examination	35	14	49
No. of patients with telephone follow-up	19	9	28
No. of patients with no ability to follow up	24	5	25
No. of patients with ruptures	2	1	3

Primary repair of flexor tendons using pure local anesthesia with the wide-awake approach allows the surgeon to do much more than test for and repair tendon gapping during surgery: it allows him or her to enter into three new important arenas of patient care.

First, it enables the surgeon to make intraoperative adjustment such as dividing pulleys and trimming or adding sutures to the repair so that the freshly repaired tendons glide through the sheath and pulleys for a full range of intraoperative active movement. Common sense would suggest that if a patient cannot achieve a full range of movement during surgery, he or she is not likely to achieve it after surgery and may end up requiring tenolysis. The authors have also had the impression that their tenolysis rate has decreased since the introduction of iTAMe, but this was not studied in this report.

Second, the surgeon is much more comfortable initiating a true active movement protocol postoperatively if he or she has seen the patient move the finger through full flexion and extension with no gapping during surgery. It becomes obvious to the operating surgeon that if the tendon repair does not gap with a full range of finger active movement during surgery, it is not likely to gap and rupture with active movement after surgery. In the beginning of the study period, both authors were using a combination of active extension, passive flexion, and place-and-hold postoperative motion regimens. However, both authors moved to active flexion protocols during the study period with increasing confidence that ruptures were not occurring because iTAMe showed an intact nongapping tendon repair with full active flexion and extension during the operation. One of the senior authors has just retired (M.B.), and the other (D.H.L.) now uses an active flexion protocol starting at day 3 after the repair with protective splints and instructions to the patient that "You can move it but you cannot use it."

Third and finally, the surgeon gets more than a full hour of uninterrupted time to talk to the non-

sedated patient during the operation and find out what type of person he or she is dealing with before deciding on the postoperative movement regimen. The patient can be educated intraoperatively on tendon rupture, scarring, and postoperative requirements for optimal results. This is greatly enhanced if the therapist can also be present at the surgery to educate the patient, as occurs in our center. The patient has an opportunity to see what the tendon appears like, buy into the process, and understand why he or she needs to follow a controlled postoperative rehabilitation program to the letter to achieve a successful outcome.

Donald H. Lalonde, M.D.

Hilyard Place, Suite C204

600 Main Street

Saint John, New Brunswick E2K 1J5, Canada

drdonlalonde@nb.aibn.com

REFERENCES

1. Lalonde DH. Wide-awake flexor tendon repair. *Plast Reconstr Surg.* 2009;123:623–625.
2. Lalonde DH. Wide-awake approach to flexor tendon repair in hand & wrist surgery. In: Chung K, ed. *Operative Techniques: Hand and Wrist Surgery*. Vol. II. Philadelphia: Saunders/Elsevier; 2007:533.
3. Thomson CJ, Lalonde DH, Denkler KA, et al. A critical look at the evidence for and against elective epinephrine use in the finger. *Plast Reconstr Surg.* 2007;119:260–266.
4. Lalonde DH, Bell M, Benoit P, Sparkes G, Denkler K, Chang P. A multicentre prospective study of 3110 consecutive cases of elective epinephrine use in the fingers and hand: The Dalhousie Project clinical phase. *J Hand Surg (Am.)* 2005;30:1061–1067.
5. Lilly SI, Messer TM. Complications after treatment of flexor tendon injuries. *J Am Acad Orthop Surg.* 2006;14:387–396.
6. Zhao C, Moran SL, Cha SS, Kai-Nan-An A, Amadio PC. An analysis of factors associated with failure of tendon repair in the canine model. *J Hand Surg (Am.)* 2007;32:518–525.
7. Tang JB. Clinical outcomes associated with flexor tendon repair. *Hand Clin.* 2005;21:199–210.
8. Peck FH, Kennedy SM, Watson JS, Lees VC. An evaluation of the influence of practitioner-led hand clinics on rupture rates following primary tendon repair in the hand. *Br J Plast Surg.* 2004;57:45–49.
9. Boyer MI, Goldfarb CA, Gelberman RH. Recent progress in flexor tendon healing: The modulation of tendon healing with rehabilitation variables. *J Hand Ther.* 2005;18:80–85.
10. Harris SB, Harris D, Foster AJ, Elliot D. The aetiology of acute rupture of flexor tendon repairs in zones 1 and 2 of the fingers during early mobilization. *J Hand Surg (Br.)* 1999;24:275–280.

Customer Service Contact Information

All correspondence concerning business matters, including subscription information, orders, or changes of address, should be directed to:

Lippincott Williams & Wilkins

16522 Hunters Green Parkway

Hagerstown, MD 21740-2116

Tel: 800-638-3030

Fax: 301-824-7390

Email: customerservice@wolterskluwer.com