

See discussions, stats, and author profiles for this publication at: <https://www.researchgate.net/publication/309449719>

Relative motion orthoses in the management of various hand conditions: A scoping review

Article in *Journal of Hand Therapy* · October 2016

DOI: 10.1016/j.jht.2016.07.001

CITATIONS

21

READS

8,671

3 authors:



Melissa Hirth

Austin Health

14 PUBLICATIONS 68 CITATIONS

[SEE PROFILE](#)



Julianne W. Howell

Self employed

25 PUBLICATIONS 395 CITATIONS

[SEE PROFILE](#)



Lisa O'Brien

Monash University (Australia)

101 PUBLICATIONS 1,322 CITATIONS

[SEE PROFILE](#)

Some of the authors of this publication are also working on these related projects:



Improving the functionality of a 3D printed hand prostheses [View project](#)



Evidence Translation in Allied Health (EviTAH) [View project](#)



ELSEVIER

Contents lists available at ScienceDirect

Journal of Hand Therapy

journal homepage: www.jhandtherapy.org

Literature Abstract

Relative motion orthoses in the management of various hand conditions: A scoping review

Melissa J. Hirth B (OT), MSc (Hand & Upper Limb Rehab)^{a,b,c,*}, Julianne W. Howell PT, MS, CHT^d,
 Lisa O'Brien PhD, B App Sci (OT), M Clin Sci (Hand & Upper Limb Rehab), Grad Dip Ergonomics, Grad Cert
 Clinical Research Methods^b

^a Occupational Therapy Department, Austin Health, Melbourne, Australia

^b Department of Occupational Therapy, Faculty of Medicine, Nursing and Health Sciences, Monash University, Frankston, Australia

^c Malvern Hand Therapy, Malvern, Melbourne, Victoria, Australia

^d Samaritan Health Services, Samaritan Orthopaedics, Corvallis, OR, USA

ARTICLE INFO

Article history:

Received 16 February 2016

Received in revised form

19 May 2016

Accepted 11 July 2016

Available online xxx

Keywords:

Relative motion

Merritt splint

ICAM

Extensor tendon

Sagittal band

Boutonniere

ABSTRACT

Study Design: Scoping review.

Introduction: The relative motion (RM) concept and immediate controlled active motion (ICAM) program, originally applied after zones IV-VII extensor tendon repairs, have been modified and extended to a variety of hand conditions, such as sagittal band injury, boutonniere deformity, and extensor lag.

Purpose of the Study: To scope the published and unpublished literature to review ICAM modifications, hand conditions for which the RM concept is used, and describe the preferred degree of relative metacarpophalangeal joint extension/flexion reported and spectrum of orthosis design.

Methods: Electronic and manual searches of scientific and gray literature and expert consultation were conducted. Documents with quantitative data were assessed with Oxford Levels of Evidence and the Structured Effectiveness Quality Evaluation Scale.

Results: Fifteen references met the inclusion criteria; 1 was level III evidence, and others were level IV evidence. RM-ICAM modifications, preferred degree of relative extension/flexion, orthotic design, management of other hand conditions and knowledge gaps were identified.

Conclusion: RM orthoses may improve outcomes in a variety of hand conditions; however, high-quality studies that contribute to the evidence base for its use are needed.

Level of Evidence: Not applicable.

© 2016 Hanley & Belfus, an imprint of Elsevier Inc. All rights reserved.

Background

The concept of relative motion (RM) for the management of zones V-VI extensor tendon (ET) repairs was first studied in cadavers in the 1970s¹ and introduced in clinical practice in 1981² by the hand surgeon Wyndell H. Merritt and his therapy colleagues, Maureen Hardy and Sandra Robinson. Historically, the idea of moving ET repairs in zones V-VI evolved from observing complications such as stiffness and adhesions caused by prolonged immobilization of the wrist and fingers after tendon repair. The original RM orthosis consisted of separate but connected wrist and finger components.³ The wrist was positioned in 25°–30° extension; the finger interphalangeal joints were held in an extension

gutter, and the metacarpophalangeal joint (MCPJ) of the injured digit was positioned in 25°–30° more extension relative to the uninjured MCPJs (Fig. 1).³

The original concept of RM theorized that multiple tendons originating from one muscle, such as the common extensors, could be positioned in such a way as to protect or unload the injured/ repaired tendons, while also limiting the excursion of the injured tendons.⁴ Cadaver and biomechanical evidence supports the RM proof of concept. In addition to the cadaver study undertaken by Dr Merritt et al^{3,5} to develop the theoretical concept, 2 further cadaver studies investigated the biomechanics of RM orthoses, for zone VI ET⁶ and zone III flexor tendon repairs.⁷ Sharma et al⁶ noted decreased strain on intact and repaired tendons when tested in the RM orthoses. Although the common extensor muscle belly is thought to be an important factor in limiting force applied to the tenorrhaphy,⁸ the role of the juncturae tendinum (JT) on repairs proximal to zone V warrants further investigation.⁶

* Corresponding author. Occupational Therapy Department, Austin Health, Waterdale Road, Heidelberg West, Victoria 3081, Australia. Tel.: +61 3 9496 2197.
 E-mail address: melissa.hirth@austin.org.au (M.J. Hirth).

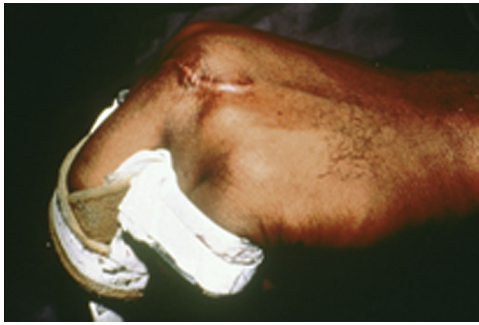

Fig. 1. Original relative motion extension orthosis. Photo courtesy of Sandy Robinson.

During the 40-year history of RM, the concept has evolved with elimination of the finger gutter and linking strap,³ a reduction in the degree of relative extension,³ and elimination of the wrist orthosis in ETs in zones V and VI.^{9–11} Use has also expanded to include extensor repairs in zones IV³ and VII^{3,12} and sagittal band (SB) injury¹³ or repair.¹² Most recently, the RM concept has been applied to manage acute and chronic boutonniere deformity^{8,14} and to decrease hand pain (personal communication between MH and Dr Donald Lalonde and personal communication between MH and Amanda Higgins). The versatility of the RM orthosis for various neurologic and/or orthopedic problems affecting MCPJ alignment, balance, or range of motion (ROM) has also been documented.¹⁵ The RM concept has since been expanded to the management of postoperative tendon transfers, flexor tendon and digital nerve repairs,¹ interosseous muscle tears,¹⁴ and as a therapeutic technique to address joint stiffness⁸ and extensor lag.¹⁴ Supporters claim advantages, such as its small size,⁹ low-profile design,^{3,10,13} simple and inexpensive fabrication,^{9,10,16} and the benefits of decreased rehabilitation time,^{3,4,11,12} early functional hand use,^{3,9,11,12} early return to work (RTW),^{9,12} improved patient adherence,^{9,16} and less financial investment for the patient or compensation carrier.⁴

Nomenclature

The RM orthosis as it is known today has had many different names. In honor of Dr Merritt, it has been called the Merritt splint^{17–19} and the Wyndell Merritt splint.¹⁰ In 2005, Howell et al³ changed the name to the acronym ICAM (immediate controlled active motion) to emphasize that it was not the usual dynamically assisted extension orthosis but immediate and active mobilization, for ET repairs. The orthosis has also been referred to as a yoke,^{19,20} a border digit splint,²¹ and an SB bridge splint.^{13,22} Most recently, to minimize confusion concerning the name of the concept and orthosis, Merritt¹ and Lalonde suggested use of the terms, relative motion *extensor* and relative motion *flexor*, dependent on the relative position of the injured digit MCPJs to the neighboring uninjured digit MCPJs.

It is important for us to point out that the terms relative motion extension (RME) and relative motion flexion (RMF) used throughout this article refer to the relative position of the injured digit rather than to a flexor or ET injury. We have also used the terms orthosis and orthoses rather than splint and splints in accordance with the current preferred nomenclature.^{23,24} Thus, we have the following terms: RME orthosis/orthoses and RMF orthosis/orthoses.

Despite widespread use, there is very limited evidence for the therapeutic efficacy of RM. Most studies consist of either single-center case series or technical articles.

Purpose of the study

The purpose of this scoping review is to gather, synthesize, and critically examine the scope of evidence supporting the RM concept in the management of hand and finger conditions and to answer the following questions:

1. For which conditions can RME and RMF orthoses be used, and what evidence exists to support their use for each condition?
2. What degree of relative flexion or extension of the MCPJs is indicated for use in each condition?
3. For each condition, what is the preferred RM orthotic design?

The summary of parameters for this scoping review is outlined in Table 1.

Methods

Because the RM literature is scarce, a scoping review permitted us to adequately address our research questions and identify knowledge gaps through scoping the field of both published and unpublished studies and reviews.^{25,26}

We used the 5-stage framework of Arksey and O'Malley²⁵ for review of the available literature and presentations. The framework requires (1) identifying the research questions; (2) identifying relevant studies; (3) study selection; (4) charting the data; and (5) collating, summarizing, and reporting the results.²⁵ The optional sixth stage of Arksey and O'Malley²⁵ was also selected; consultation with experts in the field. Including stage 6 enabled us to take in supplementary references suggested by the experts and document their insights beyond those cited in the literature.^{25,27}

Table 1
Scoping review parameters

Scoping review parameters	
Participants	Adults who have had a RM orthosis applied in the management of a hand injury or condition
Exclusion criteria	<ul style="list-style-type: none"> ■ The content of the document was duplicated in another source (eg, multiple conference presentations given on the same topic, or a conference presentation given on published studies, with priority given to published studies) ■ If the study or presentation was given in a language other than English
Interventions	Application of either a RME orthosis or a RMF orthosis
Outcomes reported	Motion/strength <ul style="list-style-type: none"> ■ Active finger ROM ■ Active wrist ROM ■ Grip strength Tendon subluxation Pain Number of therapy sessions RTW Function <ul style="list-style-type: none"> ■ Patient self-report: standardized and nonstandardized Therapy attendance Adverse events <ul style="list-style-type: none"> ■ Complications ■ Pain and subluxation
Search terms used	PubMed search terms with similar terms for MEDLINE, EMBASE, and CINAHL: (hand injur* OR tendon injur* OR tendon) AND (splint OR splints OR relative motion OR yoke OR bridge splint OR Merritt OR immediate controlled active motion OR orthotic OR orthoses)

RM = relative motion; RME = relative motion extension; RMF = relative motion flexion; ROM = range of motion; RTW = return to work.

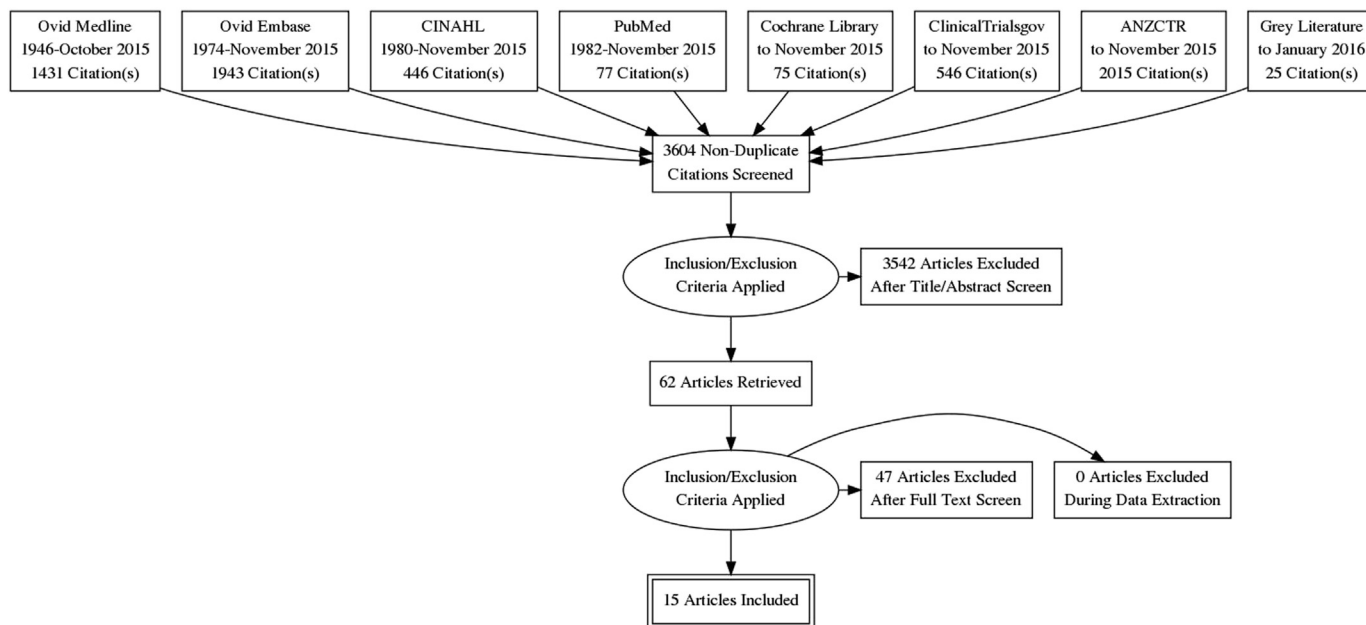


Fig. 2. Preferred Reporting Items for Systematic reviews and Meta-Analyses flow diagram.

Identification of relevant studies

Several methods were used to search the relevant literature. The original systematic electronic database search was conducted in January 2015 and repeated in November 2015 using Ovid MEDLINE, Ovid EMBASE, PubMed, and CINAHL. Other research registers searched included Cochrane Library, ClinicalTrials.gov, and the Australian and New Zealand Clinical Trials Registry. Also reviewed were bibliographies from the pertinent literature database and citation searches. In addition, the gray literature was located via manual searches of the Australian Hand Therapy Association newsletter and the American Society of Hand Therapists Times newsletter. We also personally communicated with authors of abstracts from presentations to Hand Surgery and Hand Therapy conference proceedings. All citations, abstracts, and personal communications were entered into an Excel database.

Study selection

Once entered onto the Excel database, all references were independently reviewed for inclusion by 2 reviewers (MH and JH), and differences of opinion were resolved by discussion. Inclusion criteria consisted of all articles or presentations containing qualitative or quantitative data related to the use of RM orthoses for hand injuries/conditions in adult humans. Practice forum papers that focused exclusively on orthosis fabrication or therapy plans were excluded. Where presentations and articles presented data on the same patient cohort, we prioritized the one with the most detailed data and excluded any other articles or presentations from the same patient group. Articles with the main body of the article in languages other than English were excluded. A Preferred Reporting Items for Systematic Reviews and Meta-Analyses (PRISMA) flow diagram is shown in [Figure 2](#), depicting the search results.

Charting the data

The first author (MH) independently extracted data from each reference and charted these on an Excel spreadsheet. Data chosen to help answer the research questions included author's name(s),

date, document type (publication or presentation), location of the study, sample population including age and gender, injuries treated, study aims, research approach and methodology, orthosis design, orthosis protocol, outcomes, level of evidence per the 2011 Oxford Centre for Evidence-Based Medicine,²⁸ and any other pertinent information. All authors of conference abstracts were contacted for full copies of their conference presentations to enhance quality of data extraction.

Collating, summarizing, and reporting the results

The initial step identified conditions for which RMF and RME could be used. These conditions were then separated into 3 clinical indicator categories ([Table 2](#)). For ease of analysis, we developed subcategories within the major category for protective orthoses.

To examine the level of evidence for RM use in various hand conditions, an assessment of study quality was required. Our first step in examining the evidence was to apply the Oxford Level of Evidence²⁸ ratings. The Structured Effectiveness Quality Evaluation Scale (SEQES) was implemented on studies that reported quantitative outcome data.⁴¹ The first 2 authors (MH and JH) and 5 therapy colleagues evaluated each study independently. Consensus was achieved by applying the guidelines for multiple reviewers as outlined by MacDermid.⁴¹ Outcome measures listed in [Table 1](#) were considered along with the therapy management program, orthosis design, and adverse or undesirable outcomes.

To clearly report the results of our 3 research questions, the summary table ([Table 3](#)) was developed to summarize the available evidence.

Expert consultation

Two hand surgeons¹ and 4 hand therapists² were selected to examine the scoping review. These reviewers were chosen because

¹ Dr Donald H. Lalonde, MD, FRCSC, and Dr Wyndell H. Merritt, MD, FACS.

² Maureen Hardy, PT, MS, CHT, Amanda Higgins, OT Reg(NB), Sandy Robinson, OTR, CHT, and Gwendolyn van Strien, PT, MS.

Table 2
Clinical indications reported for RM orthoses across the literature

Orthosis category	RME orthoses	RMF orthoses
Protective orthosis	<ul style="list-style-type: none"> ■ ET repair in zones IV-VII^{1-3,5,6,8-12,14,16-21,29-36} ■ Extensor apparatus repair¹⁹ ■ SB disruption <ul style="list-style-type: none"> ○ Acute (<3 wk) and subacute (<6 wk), nonsurgical^{8,13,14,22,33,34} ○ Chronic (>6 wk), nonsurgical²² ○ Acute, postsurgical^{19,32} ○ Chronic, postsurgical^{8,12,14,33,34} ■ Caput ulnae syndrome with tendon ruptures⁸ ■ ET repair and graft^{14,19} ■ ET transfer for rheumatoid ruptures in concert with synovectomies¹ ■ Fight bite with intact tendon and extensor lag¹⁹ ■ Individual MCPJ arthroplasty³⁴ ■ Infection MCPJ with extensor lag¹⁹ ■ Intrinsic tendon transfer to replace IPJ extension^{1,8} ■ Joint replacement with tendon repair or grafting¹ ■ Limit motion of split-skin graft on dorsum of hand^d (Fig. 3) ■ MCPJ and ET soft tissue injury strain¹⁹ ■ Nonrepaired (>50%) ET lacerations/disruption^b ■ <i>Lateral band snapping at PIPJ</i>^c ■ <i>MCPJ collateral ligament injury</i>^d ■ <i>Pain after trigger finger release</i>^e ■ <i>After arthroplasty PIPJ</i>^c ■ <i>Saddle syndrome (interosseous tear)</i>^c ■ <i>Swan neck deformity correction</i>^c ■ <i>Trigger finger</i>^{c, f} ■ <i>Unexplained pain about MCPJ or dorsum of hand</i>^d 	<ul style="list-style-type: none"> ■ Central slip laceration^{29,32,33} ■ Boutonniere <ul style="list-style-type: none"> ○ Acute, nonsurgical^{1,8,14,32-35,37} (Figs. 4A and 4B) ○ Open acute, postsurgical^{1,8} ○ Chronic, nonsurgical^{1,8,14,32,33,37} ○ Chronic, postsurgical^{1,8} ■ Digital nerve repair^{1,14,33,34,37} ■ Flexor tendon repair^{1,8,14} ■ Interosseous tears^{14,33,34,37} ■ <i>Lateral band sprain/tear</i>^c ■ <i>MCPJ volar plate</i>^c ■ <i>After arthroplasty PIPJ</i>^c ■ <i>Unexplained pain in palm of hand</i>^d
Exercise orthosis	<ul style="list-style-type: none"> ■ Address flexor lag^{33,37} ■ Address MCPJ extension lag^{15,32,36} ■ After MC fracture^{15,32} ■ After ET laceration³⁸ ■ Not detailed³⁶ ■ Regain IPJ flexion³⁶ ■ Regain PIPJ flexion^{14,15,32} ■ <i>Adhered flexor tendon</i>^c ■ <i>Persistent PIPJ extensor lag after release of chronic stenosing tenosynovitis, collagenase, and surgical release of Dupuytren contractures</i>^g ■ <i>PIPJ stiffness after chronic trigger finger release</i>^g ■ <i>After PIPJ arthroplasty to address PIPJ stiffness</i>^c 	<ul style="list-style-type: none"> ■ Regain active PIPJ extension^{8,36,39,40} ■ Address long ET lag^{33,37} ■ Address PIPJ extension lag¹⁴ ■ After crush/MC fracture³² ■ After ORIF MC fracture³⁶ ■ After proximal phalanx fracture and tendon repair to improve central slip activity¹⁹ ■ After gunshot wound to the MC¹⁵ ■ Regain active IPJ extension³⁶ ■ Regain active MCPJ flexion^{15,32,36} ■ <i>After arthroplasty PIPJ</i>^c ■ <i>Stiff PIPJ</i>^c
Adaptive orthosis	<ul style="list-style-type: none"> ■ After C5-C6 discectomy^{15,32} ■ Improve MCPJ alignment ■ MC head fracture,^{15,32} RA after arthroplasty,¹⁵ RA imbalances (Figs. 5A-5D),³² Parkinson disease with ulnar deviation, and ET subluxation¹⁵ ■ Preoperative functional orthosis RA ET ruptures¹⁹ ■ Reduce PIPJ subluxation in early swan neck deformity³⁶ ■ <i>Lateral band snapping at PIPJ</i>^c ■ <i>Pain after trigger finger release</i>^h ■ <i>Pain in hand of unknown origin</i>^h ■ <i>Swan neck deformity correction</i>^c ■ <i>Trigger finger, limit tendon excursion</i>^f 	<ul style="list-style-type: none"> ■ Address MCPJ alignment and RA imbalances³² ■ Ulnar nerve palsy MCPJ hyperextension¹⁵ ■ <i>Pain in hand of unknown origin</i>^h

RM = relative motion; RME = relative motion extension; RMF = relative motion flexion; ET = extensor tendon; SB = sagittal band; MCPJ = metacarpophalangeal joint; IPJ = interphalangeal joint; PIPJ = proximal interphalangeal joint; MC = metacarpal; ORIF = open reduction and internal fixation; RA = rheumatoid arthritis.

Note: Bold—included studies, Italics—added during expert consultation.

^aPersonal communication between MH and Melanie Fischer. ^bPersonal communication between MH and JH. Expert consultation: ^cGwendolyn van Strien, ^dAmanda Higgins, ^eMaureen Hardy, ^fSandy Robinson, ^gDr Wyndell Merritt, and ^hDr Donald Lalonde.

they had either published on the topic and/or had incorporated RM into clinical practice. We asked each expert to answer the 10 questions in Figure 6, provide general feedback, suggest missing references, and review the summary table (Table 3).

Results

The search strategy yielded 3604 nonduplicate references. After screening, 34 full-text articles and presentations were reviewed, and 15 of these^{3,5,9-11,13,16,18,19,21,22,29-31,39} satisfied our inclusion criteria (Fig. 2). Appendices A and B list the excluded studies, presentations, and expert opinion pieces, with our rationale for exclusion.

We sorted the 15 studies into 3 clinical applications of RM: protective, exercise, and adaptive orthoses (Table 2). In addition, RM was used for different hand conditions within the protective orthosis category; therefore, this was divided further into 3 subcategories.

1. Protective orthosis:
 - a. ET repair in zones IV-VII: 11 studies met the inclusion criteria (Table 4).
 - b. SB disruption: 3 studies met the inclusion criteria (Table 5).
 - c. Other: 2 studies met the inclusion criteria (Table 6).
2. Exercise orthosis: 1 study met the inclusion criteria (Table 7).
3. Adaptive orthosis: no studies met the inclusion criteria.



Fig. 3. Thermoplastic relative motion extension orthosis to protect skin graft.

Although a total of 15 studies met the inclusion criteria, it is important to note that a single study contributed patients to each of the 3 protective orthosis subcategories.¹⁹

Assessment of study quality

We identified 7 peer-reviewed journal articles with quantitative outcome data,^{3,9-11,13,22,30} 4 full texts of conference presentations,^{5,16,19,29} 3 conference posters,^{18,31,39} and 1 unpublished university research paper.²¹ After review of all included studies, the Oxford Level of Evidence ratings²⁸ yielded no level I or II, 1 level III,¹¹ and 14 level IV.^{3,5,9,10,13,16,18,19,21,22,29-31,39} One prospective cohort¹¹ and 9 retrospective cohort^{3,5,9,13,16,18,19,22,30} studies met the inclusion criteria, along with 2 prospective case series^{21,39} and 3 case reports.^{10,29,31} Sample sizes for the cohorts implementing RM ranged between 7 and 140 patients^{3,5,9,11,13,16,18,19,30} (mean, 39; median, 23). A further cohort²² ($n = 92$) combined data for RM with an alternate orthosis design, and hence RM data alone could not be extrapolated. The 2 case series comprise 6³⁹ and 7²¹ patients, and the 3 case reports comprise 2 single-case studies^{29,31} and 1 report on 2 cases.¹⁰ Results of quality assessment with the SEQES ranged between 11 and 30 out of a possible 48 and are presented in Table 8.

Scope of outcome measures reported

Range of motion

Measurement of ROM of the fingers was the most widely used outcome measure in all ET zone IV-VII studies. Comparison between studies was difficult because no universal outcome rating system was used and measurements were not taken at similar postoperative times. Table 9 illustrates how difficult it was to compare across studies looking at this 1 variable alone. Several

studies commented that RME orthosis yielded comparable or better ROM outcomes to dynamic mobilization^{3,9,10,21} and immobilization programs.^{3,5,9,21} In 1 study, wrist ROM was compared between 2 RME protocols, with no significant differences found at 8 weeks,¹¹ and another study documented full wrist ROM at 11.5 weeks' average follow-up.¹⁸

Of the 2 studies investigating RM for conservative management of SB injuries, only Catalano et al¹³ took before/after ROM of the involved and contralateral digits for comparison and reported full ROM at the time of final evaluation. Turner¹⁹ included 1 patient with a partial SB surgical repair (evaluated with a total active motion [TAM] rating of excellent at 12 weeks) and 1 with a partial extensor apparatus repair (rated excellent at 5 weeks). Hirth²⁹ reported ROM in a single case, which combined treatment of a zone IV and central slip repair at weeks 4, 7, and 12. In the case series of DeMott et al³⁹ focusing on joint stiffness or lag after distal metacarpal (MC) or proximal phalanx fractures, TAM scores increased on average 40% and %TAM improved from 53% to 92% with a gain in proximal interphalangeal joint (PIPJ) motion of 27° in extension or 29° in flexion observed after an average of 5 therapy sessions.

Strength

Five of the long extensor studies measured the outcome of grip strength and compared as a percentage of the uninjured hand; 85% at 7 weeks,³ 86%²¹ and 87%¹¹ at 8 weeks, 109%¹⁰ at 10 weeks, and 80%¹⁸ at 11.5 weeks after repair. Grip strength in the combined treatment of zone IV and central slip repairs was 100% at week 12.²⁹

Tendon subluxation

After intervention, Catalano et al¹³ reported no subluxation in 5 of 11 fingers with SB injuries, 3 with barely perceptible subluxation and 3 mild subluxation of the ET. Peelman et al²² reported an 84% success rate with orthosis use to resolve tendon subluxation in acute, subacute, and chronic SB incompetence.

Pain

Pain was assessed by patient self-report in the study by Catalano et al,¹³ although the method of assessment was not detailed.

Number of therapy sessions

Four long extensor studies documented the number of therapy visits.^{3,10,11,31} In the report by Burns et al¹⁰ on 2 cases, 1 attended 4 sessions and the other 2 sessions. A single case of Blakeway³¹ attended 5 sessions over 8 weeks. Svens et al¹¹ recorded an average of 5.2 sessions in their immediate relative active motion (IRAM) group and 3.6 sessions in the modified IRAM (mIRAM) group. Howell et al³ recorded an average of 8.1 visits with an average discharge at 7 weeks.

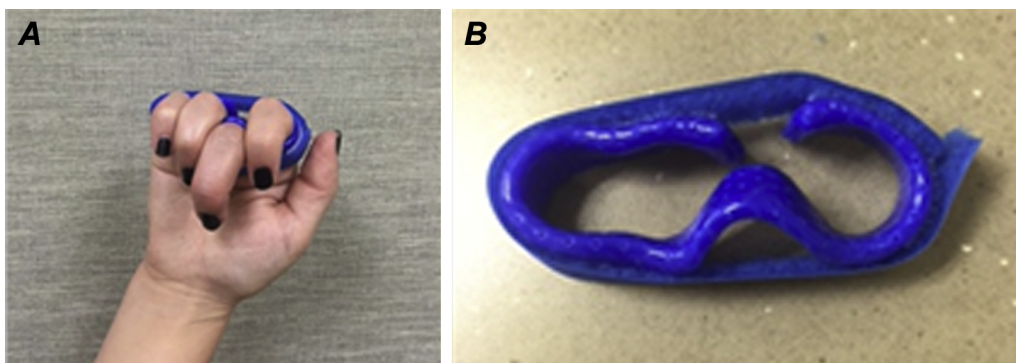


Fig. 4. (A and B) Thermoplastic and Velcro relative motion flexion orthosis for long finger boutonniere deformity.

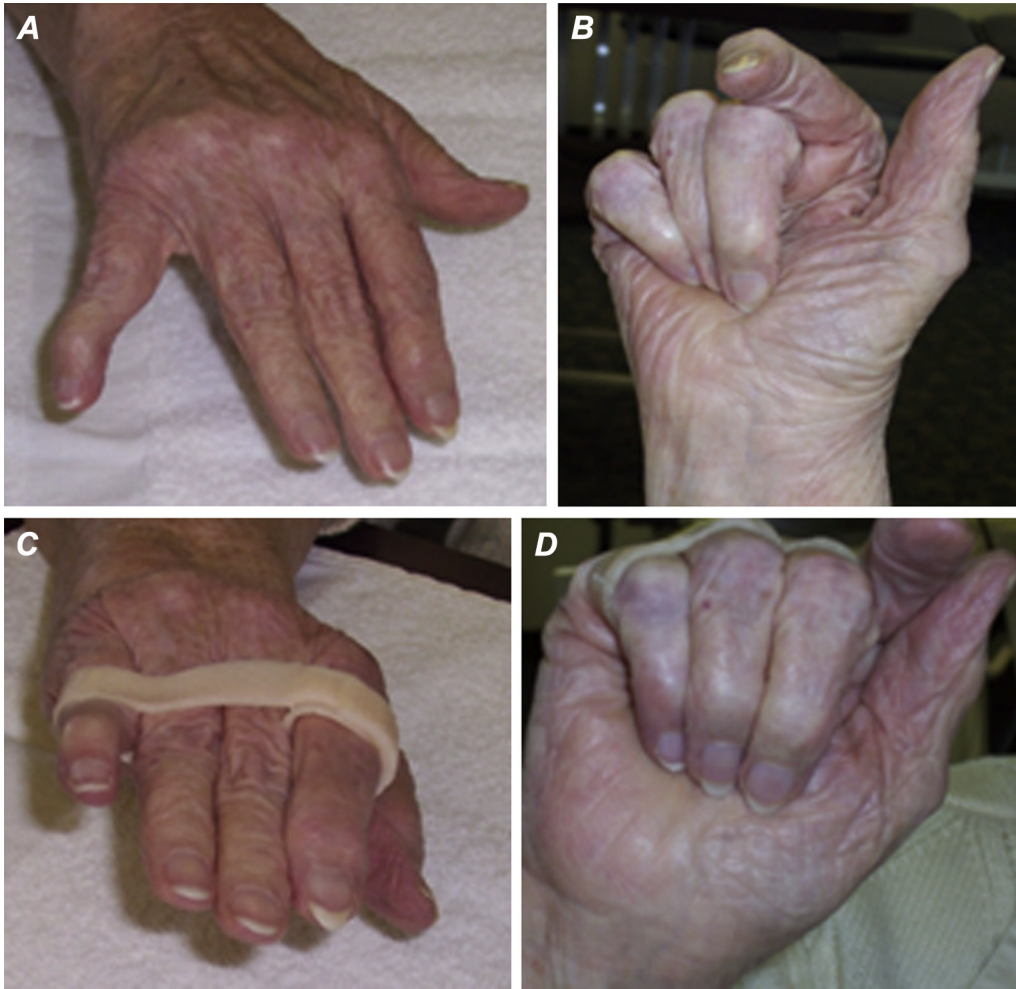

Fig. 5. (A and B) Rheumatoid arthritis with metacarpophalangeal joint malalignment and small finger decentralized extensor digitorum communis (C and D) improved alignment and balance in orthosis with index and small relative motion extension and long and ring relative motion flexion.

1) How many years you been using RM to manage hand conditions? ____ years
 2) What conditions have we NOT listed for which you have used RM?
 If we missed any condition(s), please fill in Table 2 below with the information.

Table 2: Clinical indications for relative motion orthoses

	Relative motion extension orthoses	Relative motion flexion orthoses
Category A Protective orthosis		
Category B Exercise Orthosis		
Category C Adaptive Orthosis		

3) Are you aware of any missed studies? Please provide details of missed studies.
 Before answering, please review Tables 3-6 (included studies) and Appendix 1 (excluded studies).
 4) Do you agree/ disagree with our summaries in Table 9 for each condition?
 5) Do you have any further comments regarding Table 9?
 6) Please for a moment, set your RM bias aside, do you believe the evidence presented in this SR is sufficient to support use of Relative Motion in all hand conditions?
 7) If not, where are the limitations and gaps?
 8) What is the ideal [in degree(s)] amount of relative difference for RMF? RME?
 9) Do you have any other comments regarding RM or this manuscript?
 10) Do you agree or disagree with the paragraph entitled *Orthosis and Therapy Management Program Terminology*?

Fig. 6. Questions for expert reviewers.

Table 3
Summary of scoping review findings

Indication for orthosis	Available evidence	Degree of relative extensor or flexion	Orthosis design
1. Protective orthosis <ul style="list-style-type: none"> a. ET repair zones IV-VII b. SB disruption <ul style="list-style-type: none"> ○ Acute and subacute, nonsurgical ○ Chronic, nonsurgical ○ Acute, postsurgical ○ Chronic, postsurgical c. Other, including: <ul style="list-style-type: none"> - Boutonniere <ul style="list-style-type: none"> ○ Acute, nonsurgical ○ Chronic, nonsurgical ○ Chronic, postsurgical ○ Open acute, postsurgical - Caput ulnae syndrome with tendon ruptures - Central slip repair - Digital nerve repair - Extensor lag - Flexor tendon repair - Interosseous tears - MCPJ or PIPJ arthroplasty - MCPJ volar plate/collateral ligament injury - Partial ET laceration - Skin graft - Tendon transfer/tendon grafting 	11 studies; 371 patients suggest ample evidence to use RME after zone IV-VII ET repair. Most evidence recommends use of combined RME and wrist orthoses for ET repairs in zones IV-VII, although growing indications that the wrist orthosis may be unnecessary in zones IV-VI. Benefits of overnight resting orthosis not proven. 2 studies successfully managed nonsurgical nonrheumatoid SB injuries with RME without a wrist orthosis. Single-case study combined ET zone IV EDC and central slip in 2 fingers demonstrated versatility of RM use and did not use a wrist orthosis. Emerging evidence for RM use in boutonniere, interosseous tears, and digital nerve repairs with video case studies documented. No patient data on RM use after flexor tendon repairs.	Long ET repairs: 15°-20° relative MCPJ extension of injured digit to noninjured has been recommended vs 20°-25°, which is substantiated. Unknown relationship between the degrees of relative MCPJ extension needed to protect the repair to wrist position or zone of injury or the amount of tendon shortening with repair. These factors may be best answered on a case-by-case basis during a WALANT procedure. SB injury: 25°-35° RME has been documented. Expert opinion suggests 15°-20° RME. Expert opinion proposes visual checking tendon recentralizes and note the patient's pain response to determine adequate position. Other: No studies.	All studies molded a thermoplastic strip to fabricate RM orthoses. Caution: use firm thermoplastic not soft material to fabricate the RM orthosis because the former has supportive data. Therapist and patient preference seem to dictate choice of the original 4- or 3-finger design, thermoplastic type and thickness, Velcro or self-secured closure, options for border digits balance or injured finger only in relative extension. A self-secured-solid thermoplastic orthosis may be more user-friendly for drying after shower than a perforated Velcro-secured design. A Velcro-secured design can be fit adjusted as edema changes.
2. Exercise orthosis	6 cases incorporated RM into orthosis design and exercises at 3 wk to decrease > 30° PIPJ extensor lag after metacarpal or proximal phalanx fracture, closed, and open reduction.	The degree of RME/RMF is not critical because the orthosis is used to manage stiffness or lag developed in healing fractures.	A soft or thermoplastic material may be used to design the orthosis; however, the efficacy of the soft material to provide adequate blocking force is unknown.
3. Adaptive orthosis	Finger alignment and balance can be improved by application of a RM orthosis as documented in before and after photographs for various hand conditions such as RA.	An individualized patient-centered approach is advised. For each patient, several functional orthoses may be needed to discover the best relative position for a variety of tasks. The most important design tool is critical thinking and listening to the patient.	Therapist and patient preferences determine if a soft or rigid orthosis effectively supports function.

ET = extensor tendon; SB = sagittal band; MCPJ = metacarpophalangeal joint; PIPJ = proximal interphalangeal joint; RME = relative motion extension; EDC = extensor digitorum communis; RM = relative motion; WALANT = Wide-Awake Local Anaesthesia No Tourniquet; RMF = relative motion flexion; RA = rheumatoid arthritis.

Return to work

Time taken to return to modified or full work was reported in 5 studies involving zone IV-VII extensors. Svens et al¹¹ reported for modified duties an average of 3.9 weeks in the IRAM group and 3.2 weeks in the mIRAM group. Full work duties averaged 6.7 weeks (IRAM) and 3.7 weeks (mIRAM).¹¹ The workers of Howell et al³ returned on average at 18 days. Hirth et al⁹ returned their RME group to work at an average of 3.3 weeks compared with 9.4 weeks for their immobilized group. Retallack²¹ reported return to light duty at an average of 4.6 days and full duty 20.7 days, and in another single case, light-duty work was resumed at 8 weeks.³¹ For the case of combined zone IV and central slip injuries, he returned to fence building at 6 weeks and full duty at 12 weeks.²⁹ No work data were noted in the SB, fracture, or suture technique reports.^{13,19,22,30,39}

Function

Svens et al¹¹ modified part 2 of the standardized patient evaluation measure, and the modified mean raw and percentage mean patient evaluation measure scores improved over time for both IRAM and mIRAM groups. In the case series using RM to reduce extensor lag, a nonstandardized functional goal rating was used to compare pre-morbid status (100%) with postfracture function.³⁹ The

degree of improved function in this series of 6 cases increased from a mean initial rating of 44% to a mean final rating of 91% for the 6 cases.³⁹ A 1-time Disabilities of the Arm, Shoulder and Hand measurement was obtained at discharge for a single ET patient with no other score to compare.³¹

Therapy attendance

Therapy nonattendance was noted in a few studies.^{3,11,18,19,22} Howell et al³ noted that 73% of patients completed the 21-day ICAM program. Similarly, Svens et al¹¹ recorded that 30% of patients failed to attend follow-up at 8 weeks after repair. Turner¹⁹ in a retrospective audit found that 41% of patients either cancelled or failed to attend appointments, and Izadpanah et al¹⁸ also in a retrospective review noted that only 55 of 615 (9%) patients completed their 10-week study protocol. Peelman et al²² recorded that 13 (12%) of 107 patients did not return for follow-up after the initial office visit.

Therapy management programs

A program tailored to the patient is essential and dependent on the patient's progress.^{3,9,10} To reflect this need for an individualized

Table 4
Protective orthosis: ET repair in zones IV-VII

Postoperative or conservative management: ET repair in zones IV-VII										
Author/s (location) year Document type, details	Title	Sample populations	Injuries treated	Aims	Research approach/ methodology	Orthosis design	Orthosis protocol	Outcomes	Level of evidence	Comments, tips, and clinical pearls
Robinson et al ⁵ (United States) 1986 <i>Conference presentation:</i> ASHT Annual Meeting, New Orleans, LA	A new splint design for immediate active motion following extensor tendon repair	<i>n</i> = 23 26 ET in zones V and VI (not separated by zone) 8 index, 8 middle, 2 long and ring, 1 ring and small, 4 small	ET zones V-VI	Introduced concept of RME program Challenged standard of immobilization	Retrospective cohort (1983-1986)	RME: Thermoplastic and Velcro Wrist: Thermoplastic and Velcro in wrist extension	RME and wrist orthoses: 4 /52 followed by buddy strapping for an additional week	ROM: <i>n</i> = 22; full ROM 4 wk, no joint stiffness, and no therapy required on orthosis discharge Complications: 1 patient removed orthosis at 1 wk, ruptured, re-repaired, and achieved full ROM	IV	Recommending motion not immobilization
Retallack ²¹ (Australia) 2002 <i>Unpublished research:</i> Curtin University of Technology, Australia. Hand and Upper Limb Rehabilitation Diploma	A review of the effectiveness of the border digit splints in the treatment of extensor tendon repairs in zone V and VI	<i>n</i> = 7; 6 males and 1 female Mean age: 42 y (26-59) Hand injured: 3 dominant and 4 nondominant 7 zone V 3 index, 3 long, and 1 ring	Single-zone V ET	Evaluated use of border digit program	Case series—prospective	RME: Thermoplastic injured MCPJ in relative extension Forearm-hand-finger: Thermoplastic wrist 30° extension, finger joints extension	RME: Wear 4/52 daytime Forearm: 6/52 overnight RTW and function: Surgeon advised RTW; immediate use of hand for ADLs	ROM: TAM = 255° mean (221-295) Grip: 86% of other hand RTW: Light duty 4.6 d, normal duty 20.7 d Complications: 1 patient had an extensor lag of 14° at the MCPJ and 5° at the PIPJ at 8 wk	IV	Referred to RME orthosis as border digit splint A figure shows a 3-finger orthosis design, suggesting this is an option for management
Howell et al ³ (United States) 2005 <i>Scientific article:</i> <i>Journal of Hand Therapy.</i> 18(2):182-190	Immediate controlled active motion following zone 4-7 extensor tendon repair	140/192 completed Simple = 89 Complex = 51 87% males 86% dominant hand Mean age: 34 y (11-77) 14 zone IV 112 zone V 9 zone VI 5 zone VII 49 index (35%) 50 long (36%) 27 ring (19%) 14 small (10%)	Zone IV-VII EDC, EI, and/or EDM Simple and complex	1. Provided proof of concept with cadaver and patient cases 2. Stated outcomes 3. Described ICAM orthotic fabrication and program	Retrospective cohort (1984-1994) Data analyzed from patients treated a minimum of 21 d	RME: Thermoplastic and Velcro Injured MCPJ in 15°-20° relative extension Balance border digit configuration Wrist: Thermoplastic and Velcro 20°-25° wrist extension	RME and wrist orthoses: Phase 1: 0-21 d both orthoses full time Phase 2: 22-35 d RME 24/7; add wrist orthosis for heavy tasks Phase 3: 36-49 d RME wrist orthosis only, cease wrist orthosis RTW and function: Immediate functional and light-duty hand use	ROM: Miller's criteria plus IV matched to contralateral digit Extension loss: 114 excellent, 21 good, and 5 fair Flexion loss: 111 excellent, 20 good, and 9 fair Grip strength: 85% of contralateral Complications: Nil Discharge: 49 d average RTW: 18 d average Therapy visits: 8.1 average		Dr Merritt's editorial advised repair and ICAM start within 48 h of injury Included simple and complex injuries

Berry et al ¹⁶ (United States) 2008 <i>Conference presentation:</i> AAHS Annual Meeting, Beverley Hills, CA Abstract in: <i>Hand.</i> 3(2):173	Analysis of limited Wyndell-Merritt splint for extensor tendon injuries to hand immobilization	2 groups Group A: RME orthosis only; <i>n</i> = 14 1 zone IV, 11 zone V, and 2 zone VI 5 index, 7 long, 1 ring, 1 small Group B: <i>n</i> = 7; RME and wrist orthoses 2 zone IV, 3 zone V, and 2 zone VI 3 index, 3 long, and 1 ring	ET zone IV-VI	Compared ROM results between groups and with previous studies	Retrospective cohort (2002–2008)	RME orthosis RME + wrist orthosis	Initially all immobilized <i>Average days into RME:</i> Group A: 8.8 Group B: 9.8 <i>Treatment duration:</i> 45 d Limited details	ROM: TAM Group A flexion: 230.4° Group B flexion: 230.7° Group A extensor lag: 7.5° Group B extensor lag: 10.7° <i>Complications:</i> 1 patient in each group required tenolysis for the complaint of skin adhesion	IV	The extensor lag was less in patients with a mobile wrist
Hirth et al ⁹ (Australia) 2011 <i>Scientific article:</i> <i>Hand Therapy.</i> 16(4):86–94	Early return to work and improved range of motion with modified relative motion splinting: a retrospective comparison with immobilization splinting for zones V and VI extensor tendon repairs	2 groups RME (mRMS): <i>n</i> = 23, 22 males; 1 female. Mean age: 37.2 (19–72) 21 zone V, 2 zone VI 8 index, 10 long, 3 ring, 2 small <i>Immobilized:</i> <i>n</i> = 16, 13 males; 3 females. Mean age: 39.4 (18–69)	Single ET zones V-VI lacerations; ± MCPJ capsular repair	Compared RME orthosis only with immobilization	Retrospective cohort (1999–2010)	<i>RME orthosis:</i> Thermoplastic 15°–20° relative MCPJ extension <i>Resting orthosis:</i> Thermoplastic wrist 30° extension, MCPJ 30° flexion, IPJ neutral	<i>Modified RME group:</i> RME orthosis day Resting orthosis night Cease night orthosis 4/52, RME orthosis heavy tasks 4–6/52 <i>Immobilization group:</i> Full-time resting orthosis 4/52	ROM: Modified RME vs immobilized—RME acquired motion earlier; statistically significant at 6 and 12 wk <i>RTW:</i> Modified RME: 3.3 wk average Immobilization: 9.4 wk average Functional hand use immediately in RME group <i>Complications:</i> Nil	IV	Compared RME with immobilization of ET zone V and VI. Used RME orthosis day and resting orthosis night
Blakeway ³¹ (UK) 2013 <i>Conference presentation (poster):</i> IFSHT Conference, New Delhi, India	New directions for extensor tendon management: the immediate controlled active motion (ICAM) regime—a case report	Case Study 1 zone V long finger	Zone V ET long	Documented use of ICAM in self-employed mason	Case report	<i>RME orthosis:</i> Thermoplastic 15°–20° relative MCPJ extension <i>Wrist:</i> Thermoplastic and Velcro 20°–25° wrist extension	<i>RME and wrist orthoses:</i> Full-time wear 3/52 Wk 3–5: RME only except wrist orthosis at night and protection wk 5–7: RME day for protection and night; no wrist orthosis	ROM: 8 wk %TAM—90% <i>Complications:</i> Mild scar adhesion over dorsal MCPJ at 8 wk <i>Discharge:</i> 8 wk <i>RTW:</i> Light duties before 8 wk <i>Therapy visits:</i> 5	IV	The ICAM regime provides benefits for patients as it allows for light movement and function from day 1 postoperatively
Burns et al ¹⁰ (United States) 2013 <i>Scientific article:</i> <i>Hand.</i> 8(1): 17–22	Wyndell Merritt (ICAM) protocol following zone IV-VII extensor tendon repairs: review of literature, orthosis design and case study—a multimedia article	Two case studies 2 zone V: 1 index, 1 long	Zone V ET; case 1—ET/hood laceration	Reported 2 RME orthosis—only cases and videoed orthosis fabrication	Case reports (2 patients)	<i>RME:</i> Thermoplastic and Velcro Used the border digit concept of Howell et al ³	<i>RME:</i> Orthosis applied: 1 wk and 11 d after repair Full-time wear 4/52; no heavy lifting. Functional use 4/52 without orthosis; no passive stretch before 6 wk	ROM: Case 1: full AROM 6/52; PIPJ lags Case 2: Full AROM 4/52 Both cases no MCPJ hyperextension <i>Grip strength:</i> Case 1: 10/52 comparable to contralateral <i>Complications:</i> Nil	IV	Multimedia manuscript videoed fabrication of RME orthosis and case study

(continued on next page)

Table 4 (continued)

Postoperative or conservative management: ET repair in zones IV-VII										
Author/s (location) year Document type, details	Title	Sample populations	Injuries treated	Aims	Research approach/ methodology	Orthosis design	Orthosis protocol	Outcomes	Level of evidence	Comments, tips, and clinical pearls
Altobelli et al ³⁰ (United States) 2013 <i>Scientific article: Journal of Hand Surgery.</i> 38A:1079-1083	Outcomes of digital zone IV and V and thumb zone T1-TIV extensor tendon repairs using a running interlocking horizontal mattress technique	8 patients/9 tendon lacerations thumb = 3/9 not treated with RM 6 ET in 5 patients treated with RM 4 males; 1 female Mean age: 29.2 (19-49) Zone IV ET (1 index) Zone V ET (1 index, 2 long, 2 ring)	Zone IV and V ET Sharp, nonsegmental loss lacerations	Investigated the efficacy and safety of the RIHM repair when used with ICAM (fingers) or dynamic (thumb) orthoses	Retrospective cohort (August 2009-April 2012)	<i>RME orthosis:</i> Thermoplastic 15° relative MCPJ extension <i>Wrist:</i> Thermoplastic 20°-25° wrist extension <i>Resting orthosis:</i> Thermoplastic wrist neutral, MCPJ and IPJs 0°	<i>RME and wrist orthosis:</i> Phase 1: 0-21 d both orthoses full-time Phase 2: 22-35 d RME 24/7 Phase 3: 36-49 d RME orthosis worn progressively less Strengthening at 8 wk <i>Resting orthosis:</i> Night for 6/52	<i>ROM:</i> Millers criteria Excellent = 4 Good = 2 (5° loss of MCPJ flexion) <i>Complications:</i> Nil	IV	Per authors: RIHM suture not advised in complex injuries with ET fraying or segmental tendon loss RIHM technique is technically difficult in zone VI
Izadpanah et al ¹⁸ (Canada) 2015 <i>Conference presentation (poster): AAHS Annual Meeting.</i> Paradise Island, Bahamas	Modified Merritt splint in zones IV, zone V and distal zone VI extensor tendon injuries: nine years rehabilitation experience in a single centre	n = 55, 55 fingers Age range 18-65 20 zone IV, 20 zone V, 5 zone VI Index most common (54%) followed by long and ring	Single digit, uncomplicated ET injuries with isolated ET laceration Proximal zone IV, zone V, and distal zone VI	Assessed outcomes using modified Merritt orthosis in acute ET repairs	Retrospective cohort (January 2004-March 2014) Data analyzed from patients who completed the 10-wk study protocol	<i>RME orthosis:</i> Thermoplastic	<i>RME:</i> Wear full time 4/52 Week 4: exercises out of orthosis, wear orthosis between exercises and night ; Weeks 5 and 6: buddy tape medium—heavy tasks; Week 7: discharge RME	<i>ROM:</i> Taken on average 11.5 wk Full wrist ROM Average TAM 265° <i>Grip strength:</i> Grip ≥ 80% of noninjured hand <i>Complications:</i> Nil	IV	Similar findings to Merritt and Saldana; thus, modified Merritt orthosis (RME without wrist orthosis) is an appropriate postoperative treatment
Svens et al ¹¹ (Australia) 2015 <i>Scientific article: Journal of Hand Therapy.</i> 28(1):11-18	Relative active motion programs following extensor tendon repair: a pilot study using a prospective cohort and evaluating outcomes following orthotic interventions	2 groups <i>IRAM:</i> n = 45, 40 males; 5 females; mean age: 35 (18-76) 2 zone IV, 35 zone V, 12 zone VI 23 index, 12 long, 5 ring, 8 small <i>mIRAM:</i> 18 patients, 14 males; 4 females; mean age 35 (19-71) 1 zone IV, 12 zone V, 5 zone VI 8 index, 5 long, 3 ring, 3 small [†]	60 single ET, 3 participants had 2 fingers injured Zones IV-VI, full laceration, with or without capsular repair	Compared 4-6 wk program and IRAM to ICAM ³	Prospective cohort (April 2009-January 2013)	<i>RME:</i> Thermoplastic <i>Wrist:</i> Thermoplastic and Velcro	<i>IRAM:</i> Day 1-21—RME + wrist orthoses 3/52; avoid hand use; day 22-35—wean from wrist orthosis; wear RME added 2 wk; 12 wk no restrictions <i>mIRAM:</i> Day 1-21—RME-only if repair distal to JT; RME + wrist if proximal or EDM; day 22-28 wean from wrist orthosis; if no lag cease orthosis 4/52; no restrictions 36 d	<i>Finger and wrist ROM:</i> <i>IRAM vs ICAM³:</i> similar outcomes except IRAM > Fair ratings per Miller's criteria, longer hand use restriction, and less therapy visits <i>IRAM vs mIRAM:</i> mIRAM more rapid recovery of ROM, grip, better PEM scores, fewer therapy sessions, and sooner RTW <i>Complications:</i> IRAM group: 2 developed wound infection treated with oral antibiotics, 6 required treatment for persistent edema; 1 continued to have edema and finger stiffness for more than 8/52	III	Comparable outcomes with those previously published and similar between the 4-wk and 6-wk orthotic interventions

Turner ⁹ (UK) 2015 Conference presentation: BAHT, Liverpool, England	An audit of the use of the Merritt yoke relative motion splint for extensor tendon repair	n = 56 patients, 65 digits 46 males and 10 females Age range: 15–85 Data available: 31 full/partial ET 4 zone IV, 18 zone V, 9 zone VI Fingers injured not detailed	ET zones proximal IV-VI Full/partial (> 40%) ET and extensor hood lacerations, and partial SB	Reported audit results	Retrospective cohort (April 2013–March 2015)	RME: Thermoplastic Hand-based extension night orthosis—thermoplastic Wrist: Forcarm-based—thermoplastic or Futuro brace	RME: Surgery averaged 5 d; therapy initiated average 6–7 d postsurgery (4–15 d) Duration: 5 wk Light hand use permitted if lag is present initially, consider another orthosis, eg, hand or wrist at night	ROM: Note: All ET zones—full/partial repair data pooled TAM, n = 30 excellent, 3 good, and 22 unknown Complications: Some extensor lag or reduced secondary to tendon adherence	IV	High failed to attend rate Although not a part of this retrospective cohort, 1 ET zone VII rupture occurred secondary to noncompliance
---	---	---	---	------------------------	--	--	--	---	----	--

ET = extensor tendon; ASHT = American Society of Hand Therapists; RME = relative motion extension; ROM = range of motion; MCPJ = metacarpophalangeal joint; RTW = return to work; ADLs = activities of daily living; TAM = total active motion; PIPJ = proximal interphalangeal joint; EDC = extensor digitorum communis; EI = extensor indicis; ICAM = immediate controlled active motion; AAHS = American Association for Hand Surgery; mRMS = modified relative motion splint; IPJ = interphalangeal joint; IFSHT = International Federation of Societies for Hand Therapy; AROM = active range of motion; RIHM = running interlocking horizontal mattress; PEM = patient evaluation measure; IRAM = immediate relative active motion; mIRAM = modified immediate relative active motion; BAHT = British Association of Hand Therapists; SB = sagittal band.
* EDM or zone VI were treated with wrist orthosis also.

approach, we have chosen to use the phrase therapy management programs instead of protocol.

Initiation of RM orthosis program

1. Protective orthosis

a. Long extensor repairs—zones IV–VII

Across all studies, the average time to initiate RME was 5 days postsurgery, with most commencing by day 7.^{3,5,9-11,16,18,19,21,30,31} Outliers were 8.8 and 9.8 days¹⁶ and 11 days.¹⁰

b. SB disruption

Catalano et al¹³ used the RM orthosis for acute injuries; all were diagnosed and treated within 4 weeks of injury, with an average of 14.8 days from injury to diagnosis. Peelman et al²² categorized all patients managed as either acute (within 3 weeks), subacute (between 3 and 6 weeks), or chronic (greater than 6 weeks) after injury or onset of symptoms. In a single case, management was initiated on the first therapy visit.¹⁹

c. Other—combined zone IV ET and central slip repair

Therapy management was commenced 10 days after repair.²⁹

2. Exercise orthosis

The RM orthosis was implemented as an adjunct to the therapy program in 6 patients on average 22 days after distal MC or proximal phalangeal fracture reduction.³⁹

Type of orthosis, wearing regimen, and progression plan

1. Protective orthosis

a. Long extensor repairs—zones IV–VII

The original ET zones V–VI study⁵ required wear of both the wrist and RME orthoses for a period of 4 weeks, followed by buddy strapping to an adjacent digit for an additional week. Later, Howell et al³ added zones IV and VII and divided the program into 3 phases defined by days after tendon repair. The ICAM program required both the RME orthosis and a wrist orthosis to be worn continuously for 21 days after repair; at day 22, the wrist orthosis was removed for light duty and worn with the RME orthosis for medium to heavy duty until day 36; after which, the wrist orthosis was discarded, and only the RME orthosis worn until 7 weeks after repair.³

The main differences between the earlier and later studies are no wrist orthosis, use of a night resting orthosis, and duration of orthosis wear. Retallack²¹ (zone V) and Hirth et al⁹ (zones V and VI) did not use a wrist orthosis, yet did use a night resting orthosis. Hirth et al⁹ ceased the night orthosis at 4 weeks and Retallack²¹ at 6 weeks. Altobelli et al³⁰ followed the ICAM program³ and added a night resting orthosis for 6 weeks. Berry et al¹⁶ (zones IV, V, and VI), Burns et al¹⁰ (zone V), Izadpanah et al¹⁸ (zones IV–distal VI), and Turner¹⁹ (zones IV–VI) used only the RME orthosis. Turner¹⁹ added a wrist or night resting orthosis if an extensor lag presented. The comparison group of Berry et al¹⁶ wore both components. The IRAM group of Svens et al¹¹ wore both components, and the mIRAM group wore the RME orthosis only when the repair was distal to the JT (zones IV–V) and both components when the repair was proximal to the JT (zone VI) and/or involved the extensor digiti minimi (zones IV–VI). Wrist orthoses were

Table 5
Protective orthosis: SB disruption

Postoperative or conservative management: SB disruption										
Author/s (location) year Document type, details	Title	Sample populations	Injuries treated	Aims	Research approach/ methodology	Orthosis design	Orthosis protocol	Outcomes	Level of evidence	Comments, tips, and clinical pearls
Catalano et al ¹³ (United States) 2006 <i>Scientific article:</i> <i>Journal of Hand Surgery.</i> 31A(2):242-245	Closed treatment of nonrheumatoid extensor tendon dislocations at the metacarpophalangeal joint	10 patients/11 injuries. 8 females/2 males, mean age 54.1 (18-89); Excluded RA; treated within 4/52 of injury	Acute SB injuries of ring and long fingers with complete ET dislocation	Described nonsurgical treatment	Retrospective cohort (time frame not detailed)	RME: SB bridge splint Thermoplastic: Injured MCPJ 25°-35° relative extension	RME: Long finger and ring finger injuries only 8-wk full-time wear	Follow-up: 14 mo average ROM: All had full ROM Pain and ET subluxation or dislocation: n = 3 moderate pain and mild subluxation (failure) Treatment duration: Range 3-16 wk Pain and ET subluxation or dislocation: Subluxation resolved 77/92 patients: acute 39/41 traumatic and 4/4 atraumatic and chronic 10/15 traumatic and 8/14 atraumatic 8 patients elected surgery ROM: TAM excellent n = 1 at 12 wk	IV	RME orthosis = SB bridge splint
Peelman et al ²² (United States) 2015 <i>Scientific article:</i> <i>Journal of Hand Surgery European Volume.40E(3):287-290</i>	Splintage in the treatment of sagittal band incompetence and extensor tendon subluxation	n = 92 patients; 101 digits 42 men, 50 women Mean age: 56 (18-94); excluded RA Subluxation = frank translocation into intermetacarpal valley 2 cohorts and 3 subgroups	SB cohorts: Traumatic (T) atraumatic (AT) Subcategories: Acute ≤ 3 wk Subacute 3-6 wk Chronic > 6 wk	Evaluated outcome of orthotic wear and effect of time on outcome	Retrospective cohort (2000-2010)	Two orthoses designs: Forearm-hand-finger based: All digits P1 block, thermoplastic RME: SB bridge splint described by Catalano et al ¹³ Thermoplastic and strap	RME: Wear first visit-6/52 full time Part-time wear option additional 2-4 wk	Pain and ET subluxation or dislocation: Subluxation resolved 77/92 patients: acute 39/41 traumatic and 4/4 atraumatic and chronic 10/15 traumatic and 8/14 atraumatic 8 patients elected surgery	IV	RME orthosis = SB bridge splint Two orthosis designs not sorted in statistical analysis
Turner ¹⁹ (UK) 2015 <i>Conference presentation:</i> BAHT, Liverpool, England	An audit of the use of the Merritt yoke relative motion splint for extensor tendon repair	n = 55 patients, 65 digits 46 males and 10 females Age range: 15-85 Data available: 1 partial SB	ET zones proximal IV-VI Full/partial (> 40%) ET and extensor hood lacerations, and partial SB	Reported audit results	Retrospective cohort (April 2013-March 2015)	RME: Thermoplastic	RME: Partial SB 4 wk Light hand use permitted	ROM: TAM excellent n = 1 at 12 wk	IV	3 patients identified in the audit, data available on 1 patient only

SB = sagittal band; RA = rheumatoid arthritis; ET = extensor tendon; RME = relative motion extension; MCPJ = metacarpophalangeal joint; ROM = range of motion; BAHT = British Association of Hand Therapists; TAM = total active motion.

Table 6
Protective orthosis: other—combined EDC and central slip repair, and extensor apparatus repair

Postoperative or conservative management: other—zone IV EDC and central slip repair										
Author/s (location) year Document type, details	Title	Sample populations	Injuries treated	Aims	Research approach/methodology	Orthosis design	Orthosis protocol	Outcomes	Level of evidence	Comments, tips, and clinical pearls
Hirth ²⁹ (Australia) 2014 <i>Conference presentation:</i> AAHS, Hawaii, USA	A single case study of combining RME and RMF in one RM orthosis.	Single-case study Male Ring 50% central slip and small 80% EDC zone IV	Central slip and zone IV ET: 2 fingers	Described case study in which RMF and RME combined in same orthotic design	Case report	RME/RMF: Thermoplastic—ring finger MCPJ relative flexion and small finger MCPJ relative extension	RME/RMF: Wear full-time 4 wk, wean between 4 and 6 wk Functional hand use	ROM: ROM = IV contralateral fingers at 12 wk RTW: 6 wk in RM orthotic Discharge: 12 wk	IV	Single-case RME/RMF combination supports no need for wrist orthosis in ET zone IV
Turner ¹⁹ (UK) 2015 <i>Conference presentation:</i> BAHT, Liverpool, England	An audit of the use of the Merritt yoke relative motion splint for extensor tendon repair	n = 55 patients, 65 digits 46 males and 10 females Age range: 15-85 Data available: 1 50% extensor hood repair	ET zones proximal IV-VII Full/partial (> 40%) ET and extensor hood lacerations, partial SB	Reported audit results	Retrospective cohort (April 2013–March 2015)	RME: Thermoplastic	RME: 5 wk average per audit results permitted	ROM: TAM = IV excellent, n = 1 at 5 wk	IV	3 patients identified in the audit, data available on 1 patient

EDC = extensor digitorum communis; AAHS = American Association for Hand Surgery; RME = relative motion extension; RMF = relative motion flexion; RM = relative motion; MCPJ = metacarpophalangeal joint; ET = extensor tendon; ROM = range of motion; RTW = return to work; SB = sagittal band; BAHT = British Association of Hand Therapists; TAM = total active motion.

Table 7
Exercise orthosis

Addressing PIPJ extensor lag										
Author/s (location) year Document type, details	Title	Sample populations	Injuries treated	Aims	Research approach/methodology	Orthosis design	Orthosis protocol	Outcomes	Level of evidence	Comments, tips, and clinical pearls
DeMott et al ³⁹ (United States) 2015 <i>Conference presentation (poster):</i> AAHS, Colorado, USA	Effects of relative motion orthoses and exercise for extensor lag following proximal phalanx fractures; a case series report	n = 6; 3 males and 3 females Mean age: 26 (16–40)	Single finger distal metacarpal or proximal phalanx fracture with PIPJ extension lag > 30°	Evaluated effect of adding RM orthosis/exercises to therapy programs when PIPJ lags developed after fracture reduction	Case series—prospective	RM: Thermoplastic. RM 20°–30° to involved digit. Controlled redirection via trial-error positioning of the MCPJ to maximize optimal PIPJ extension	Wear for subacute intervention (1–4 wk) of controlled redirection during function	ROM: 40% increase in TAM after 5 sessions. Gain in PIPJ extension: 27°; flexion: 29° Function: 47% increase Complications: Nil	IV	Combined RM position into orthoses and exercises about 3 wk after fracture reduction. Ongoing data collection

PIPJ = proximal interphalangeal joint; AAHS = American Association for Hand Surgery; RM = relative motion; MCPJ = metacarpophalangeal joint; ROM = range of motion; TAM = total active motion.

Table 8
The Structured Effectiveness Quality Evaluation Scale⁴¹ scores

Scoring: 2, 1, or 0 as per evaluation guidelines ⁴¹	Robinson et al ⁵	Retallack ²¹	Howell et al ³	Catalano et al ¹³	Berry et al ¹⁶	Hirth et al ⁹	Blakeway ³¹	Burns et al ¹⁰	Altobelli et al ³⁰	Hirth ²⁹	Izadpanah et al ¹⁸	Svens et al ¹¹	Peelman et al ²²	DeMott et al ³⁹	Turner ¹⁹
	1986	2002	2005	2006	2008	2011	2013	2013	2013	2014	2015	2015	2015	2015	2015
Study question															
1. Was the relevant background work cited to establish a foundation for the research question?	1	1	1	1	1	2	1	1	1	1	1	2	1	1	1
Study design															
2. Was a comparison group used?	1	0	0	0	1	1	0	0	0	0	0	1	1	0	0
3. Was patient status at more than 1 time point considered?	1	1	0	1	0	1	1	1	0	1	1	1	1	2	0
4. Was data collection performed prospectively?	1	2	1	0	1	1	1	1	0	1	1	2	0	1	1
5. Were patients randomized to groups?	1	0	0	0	0	0	0	0	0	0	0	0	0	0	0
6. Were patients blinded to the extent possible?	1	1	1	1	1	1	1	1	1	1	1	1	1	0	0
7. Were treatment providers blinded to the extent possible?	1	1	1	1	1	1	1	1	1	1	1	1	1	1	1
8. Was an independent evaluator used to administer outcome measures?	0	0	0	1	0	0	0	0	0	0	0	0	0	0	0
Subjects															
9. Did sampling procedures minimize sample/selection biases?	0	1	2	1	1	1	1	1	1	1	1	2	1	0	1
10. Were inclusion/exclusion criteria defined?	1	2	2	2	1	2	1	1	2	1	2	2	2	1	1
11. Was an appropriate enrolment obtained?	0	0	0	0	0	0	0	0	0	1	0	1	0	0	0
12. Was appropriate retention/follow-up obtained?	0	1	1	2	1	1	2	2	2	2	0	1	2	2	0
Intervention															
13. Was the intervention applied according to established principles?	1	1	2	1	1	2	2	2	1	2	1	2	1	1	0
14. Were biases due to the treatment provider minimized (ie, attention, training)?	0	1	1	1	1	0	1	1	0	1	1	1	1	1	1
15. Was the intervention compared with the appropriate comparator?	2	0	0	0	2	2	0	0	0	0	0	2	2	0	0
Outcomes															
16. Was an appropriate primary outcome defined?	1	2	2	1	2	2	2	2	2	2	2	2	1	2	2
17. Were appropriate secondary outcomes considered?	1	2	2	1	1	2	1	1	1	1	1	2	1	1	1
18. Was an appropriate follow-up period incorporated?	1	1	1	1	1	1	1	1	1	2	1	1	1	1	0
Analysis															
19. Was an appropriate statistical test(s) performed to indicate differences related to the intervention?	0	1	0	0	0	2	0	0	0	0	0	1	2	0	0
20. Was it established that the study had significant power to identify treatment effects?	0	0	1	0	0	0	0	0	0	0	0	0	1	0	0
21. Was the size and significance of the effects reported?	0	0	0	0	0	2	0	0	0	0	0	1	1	0	0
22. Were missing data accounted for and considered in analyses?	0	0	1	1	0	1	1	1	0	0	1	1	2	0	0
23. Were clinical and practical significance considered in interpreting results?	1	1	1	1	1	2	1	0	0	1	1	2	1	1	1
Recommendations															
24. Were the conclusions/clinical recommendations supported by the study objectives, analysis, and results?	1	1	1	1	1	2	1	1	1	1	1	1	2	1	1
Total quality score (sum of aforementioned/48)	16	20	21	18	18	29	19	18	14	20	17	30	26	16	11

phased out between 22 and 35 days (IRAM) and between 22 and 28 days for the mIRAM subgroup.¹¹

Duration of RME orthosis wear. The program by Hirth et al⁹ required 4 weeks of RME orthosis wear with additional 4–6 weeks wear for heavy-duty tasks. The average duration of treatment was 45 days for both groups of Berry et al.¹⁶ Burns et al¹⁰ recommended 4 weeks, Turner¹⁹ 5 weeks, and Izadpanah et al¹⁸ 7 weeks of protected orthosis wear. Retallack²¹ discontinued the RME orthotic at 4 weeks; 6 weeks to manage lag. Altobelli et al³⁰ weaned from the orthosis between 5 and 7 weeks, Svens et al¹¹ IRAM group between 5 and 6 weeks, and mIRAM subgroup between 4 and 5 weeks; discharge from all Svens' groups required the absence of a lag. Blakeway³¹ followed the 7-week ICAM program.³

Functional use. Most followed the functional use guidelines suggested by Howell et al³ and Hirth et al,⁹ which promoted immediate light- to medium-duty use.^{19,21,31} Burns et al¹⁰ instructed patients not to lift or use their hand for heavy work during the first few weeks. The IRAM program of Svens et al¹¹ discouraged the use of the injured hand for 3 weeks and required both orthoses to be worn for light duty between weeks 3 and 5, and consideration was given at week 12 for return to heavy duty or contact sports without the orthosis. Patients in the mIRAM program were encouraged to use their hands for light activities of daily living and to RTW between 1 and 21 days and released to normal activity and heavy duty use between weeks 5 and 6.¹¹ Buddy taping for medium to heavy duty was commenced at 5–6 weeks by Izadpanah et al.¹⁸

b. SB disruption

Participants in the study by Catalano et al¹³ were instructed to wear their RME orthosis continuously for 8 weeks. Although 2 orthotic designs were used by Peelman et al,²² all participants wore the orthosis full time for 6 weeks and then part time for 2–4 additional weeks. Turner¹⁹ used the RME orthosis for 4 weeks.

c. Other—combined zone IV ET and central slip repair

The RMF/RME orthosis was worn during the day, and a hand-finger–based orthosis was worn at night for 4 weeks.²⁹ At 4 weeks, PIP joint extension lags were observed so to address the lags, only a dorsally based hand/finger extension orthosis was used overnight until discharge at week 12.²⁹

2. Exercise orthosis

Once the therapy program was initiated, the RM orthosis was worn between weeks 1–4 during functional tasks to promote controlled redirection of PIPJ motion; however, the exact daily time line was unclear.³⁹

Degree of relative flexion or extension

1. Protective orthosis

a. Long extensor repairs—zones IV–VII

The early versions of the RME orthosis had more MCPJ extension (25°–30°) relative to the adjacent uninjured MCPJs, whereas later versions reduced the difference to 15°–20° more MCPJ extension.^{3,5} Grounded on the later work, a number of authors fabricated their orthoses with 15°–20° relatively more MCPJ extension.^{9–11,16,30}

b. SB disruption

Both Catalano et al¹³ and Peelman et al²² fabricated the orthosis with the involved MCPJ in 25°–35° more MCPJ relative extension, whereas Turner¹⁹ did not specify.

c. Other—combined zone IV ET and central slip repair

Hirth²⁹ did not specify the relative positions of the involved MCPJs to each other or to the uninjured MCPJs in the case report.

2. Exercise orthosis

The involved digit is initially positioned in 20°–30° relative MCPJ extension/flexion and adjusted to maximize controlled redirected motion using a trial and error approach.³⁹

Orthosis design

1. Protective orthosis

a. ET repair

All studies included 4 fingers in their RME thermoplastic design.^{3,5,9–11,16,18,19,21,30,31} Some authors leave the RME orthosis loop open and secure with Velcro (Velcro Companies, Manchester, USA) (Figs. 7A and 7B)^{2,3,10,16} and others seal the loop to itself (Figs. 8A and 8B),^{9,18,19,21,31} and others did not comment.^{11,30}

Howell et al³ detailed a finger configuration to balance the RME orthosis for repairs that involved either the index or small finger border digit; with this design, the uninjured border digit is also positioned in relative extension (Figs. 9A, 9B, and 9C). Following this recommendation, others have fabricated their orthoses in this manner.^{10,16} The design by Hirth et al⁹ differed, irrespective of the finger injured; only the repaired digit was positioned in relative extension (Figs. 10, 11A, and 11B). Other authors did not provide details of what orthosis configuration was used involving border digits.^{5,11,18,19,21,30}

b. SB disruption

In the study by Catalano et al,¹³ only the long or ring finger injuries were treated with a 3-finger RME design, with no strap (Fig. 12). Peelman et al²² also used a 3-finger RME orthosis but with a Velcro strap over the injured finger. No border digits were managed by Catalano et al.¹³ Fourteen border digits were treated by Peelman et al,²² but it is unknown what design was used. There was no orthosis detail provided for the single case.¹⁹

c. Other—combined zone IV ET and central slip repair

A 4-finger thermoplastic design positioned the repaired small finger zone IV ET in relative extension to the ring finger, and the repaired ring finger central slip in relative flexion to the long and small finger MCPJs (Fig. 13).²⁹

2. Exercise orthosis

A classic-4-finger thermoplastic orthosis design was used.³⁹

Adverse events

After the use of RME following long ET repair, 5 studies reported no complications, whereas few complications were reported in 6 studies. Patients who completed at least 4 weeks




Fig. 7. (A and B) Thermoplastic and Velcro relative motion extension orthosis for long finger.

of orthosis intervention had no incident of tendon rupture,^{3,5,9-11,16,18,19,21,30,31} and there were no reported cases of pain syndromes.³ Three patients have been recorded as requiring further surgical intervention; 1 noncompliant patient removed his or her orthosis 1 week postoperatively, ruptured, was re-repaired, and obtained full ROM,⁵ whereas 2 others required tenolysis.¹⁶ Two subjects required oral antibiotics for wound infection, and 6 were treated for persistent edema; one of these for more than 8 weeks for persistent edema and finger stiffness.¹¹ Others mentioned mild scar adhesions,³¹ extensor lag,^{19,21} and reduced end of range flexion,¹⁹ with no additional interventions reported.

Three digits in the SB study by Catalano et al¹³ were considered failures secondary to moderate pain and mild subluxation that persisted after treatment. Of these 3 patients, 1 elected to have SB reconstruction.¹³ Eight of 22 patients in the study by Peelman²² elected to have corrective surgery. Symptom recurrence was observed in 3 patients who initially had resolution of tendon subluxation.²² No adverse events were noted in the combined extensor digitorum communis (EDC) and central slip repairs in a single case report²⁹ or in the fracture series that used RM as a treatment for PIPJ extensor lag.³⁹

Expert consultation summary

Our experts were selected for their knowledge and use of RM; 3 of the consultants pioneered the RM concept nearly 40 years ago,

and the others have 11, 20, and 27 years of clinical experience with RM.

We asked our experts to review and add any information they felt was missed. Their specific answers are noted in *italics* within Table 2. Interestingly, 5 of 6 reviewers added RME to manage trigger finger.

When asked if data were sufficient to support the use of RME for ET repairs in zones IV-VII, the answer was unanimously yes. Consensus was not reached for other conditions, with comments such as *“If it takes the pain away or restores balance, the answer is yes”* and *“No, not for ALL hand conditions.”* Most agreed that more evidence is needed for other applications, especially RMF and use of RME or RMF as an exercise orthosis. Surgeon reviewers felt that we needed to clearly emphasize the differences between RM management of acute, chronic, postsurgical, or nonsurgical boutonniere or SB injury. As a result, these changes have been made to the article and Table 2. Consultants were struck by the plethora of published and unpublished RM literature, which lacked outcome data, and was thus excluded. Our reviewers identified additional limitations in the body of evidence, including use of RM in young children, immune-suppressed conditions (such as rheumatoid arthritis ETs), and the nonadherent patient population.

The RM position of 15°-20° difference in MCPJ was agreeable to all. A range of comments regarding this question included: *“Whatever degree is most comfortable... yet achieving the goals of treatment,”* and *“...whatever degrees the width of a pencil simulating the orthosis creates,”* *“Individualised according to the amount of*

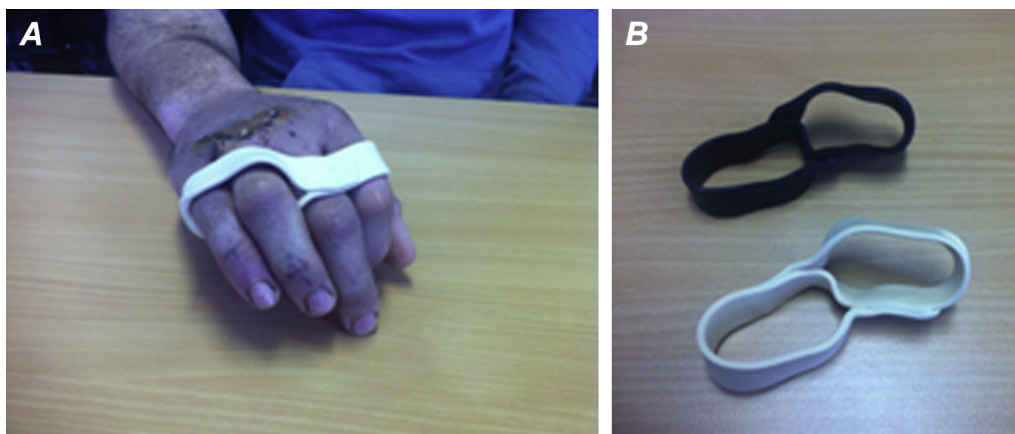


Fig. 8. (A and B) Thermoplastic relative motion extension orthosis for ring and small fingers.

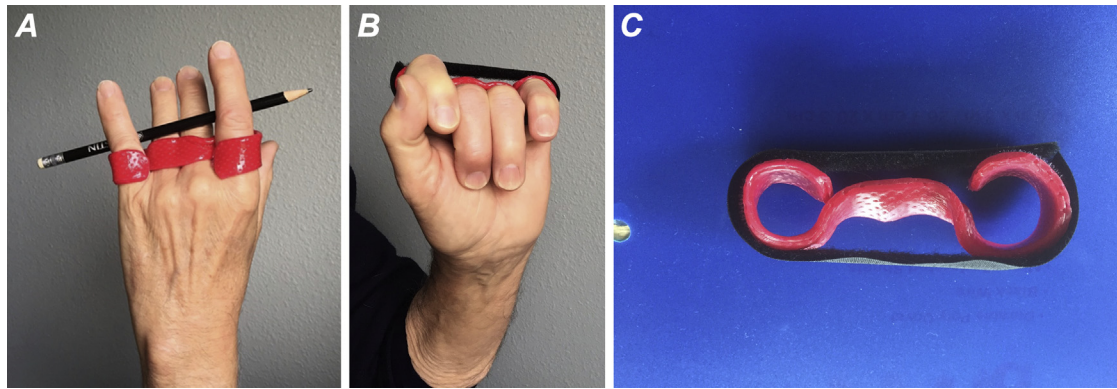


Fig. 9. (A, B, and C) Thermoplastic and Velcro relative motion extension orthosis for index or small finger showing balance configuration.

inflammation still present...”, “Relies on visual satisfaction, are structures stable, has pain resolved, is the patient satisfied how the digit is positioned during function?” and “This varies, if no wrist orthosis more extension... dependent on diagnosis... motion observed when the orthosis is in place... type of material used to make RM orthosis... type of hand use.”

All expert reviewers endorsed our proposal for consistent terminology to support clarity in reporting and future literature and data synthesis; there was also unanimous endorsement for the overall summary presented in Table 3.

Expert insights

- After ET repair, dedicate postoperative days 1–4 to elevate and immobilize for the purpose of decreasing internal bleeding, swelling, work of flexion and extension, and then apply RME.
- Try the pencil test to simulate RME or RMF to see if this takes away unexplained hand pain.
- More relative MCPJ flexion is better for treating boutonniere deformity.
- A stiff PIPJ must be passively correctable to $\leq 30^\circ$ extension to use RMF as an exercise orthosis.
- Treatment tailored to the patient is important.
- Chronic SB injury can be nonsurgically managed when there is evidence of active collagen turnover, that is, inflammation.
- Interosseous tears—1 of the most important uses of RM.
- Multination and multicentered studies are our best bet to accumulate large amounts of data.
- Use RM, but stay critical, and combine RM with other treatments.
- Concern that the wrist orthosis should not be omitted for all ET zones as there is no sufficient documentation.

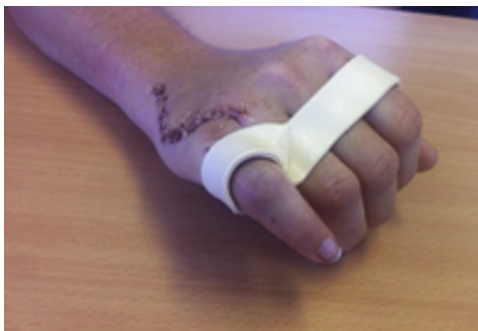

Fig. 10. Thermoplastic relative motion extension orthosis for small finger.

- After 20 years, I have yet to have my first ET rupture, many wearing only the RME orthosis.

Discussion

Although many conditions were identified as being potentially suitable for RM, most of the RM literature is dedicated to the management of long ET repairs and conservative management of SB injuries. For the most part, use of RM to manage other hand conditions is limited to single case reports or expert opinion. We have identified details often lacking or inconsistently applied, which we believe should be universally considered to adequately document RM effectiveness. Equally important is comparison of RM outcomes to existing accepted interventions for the same condition to better inform practice and improve level of evidence.

Assessment of study quality

The low SEQES scores highlighted the poor quality of evidence. Studies were largely retrospective with varying times of data collection, commonly at discharge, making review and comparison difficult. In some studies, data were pooled across conditions and different orthosis types, limiting our ability to report outcomes. Many studies lacked specific details, such as zone of injury, exact structures repaired, noting index or small finger (rather than EDC/ extensor indicis/extensor digiti minimi), and listing the number of patients instead of the number of tendon repairs.

Scope of outcome measures reported

The primary outcome measure in 14 of 15 studies was active ROM. Unfortunately, no universal outcome rating system was used, and measurements were not taken at similar postoperative times, making comparison difficult. Table 9 outlines how many different criteria were used to assess ET outcomes. We believe that use of Miller's criteria⁴³ to report extension and flexion loss plus comparison with the contralateral digit is more rigorous and makes available 3 different data sets: (1) active composite extension reflective of ET excursion, (2) active composite flexion, reflective of stiffness, and (3) direct comparison to the patient's normal motion. Grip strength taken between 7 and 12 weeks measured a range of 80%–109% of the contralateral hand appeared sufficient for hand use without compromise to the repair.

There was inconsistent reporting of RTW time, with only 6 of 15 studies recording time, and a lack of clear definitions for category of work (light, medium, or heavy) to which the patient returned. We would encourage future researchers to only use standardized outcome tools and tests, with modifications avoided to not violate




Fig. 11. (A and B) Thermoplastic relative motion extension orthosis for index finger.

reliability and validity. The number of therapy visits across studies varied, but most ranged between 5 and 8 visits over a period of 6–8 weeks, with some final follow-up visits extended to 12 weeks after repair. Since the time the ICAM guidelines were published, the literature shows the number of visits and duration of therapy to be decreasing; therefore, this should be noted by future researchers.

We acknowledge that therapists do have the option to select from therapy management programs other than RM.^{44–58} Compared with other postoperative ET zone IV–VII management programs, RME yielded similar or better ROM outcomes to immobilization, early controlled mobilization, and early active mobilization as detailed in systematic review findings by Talsma et al⁵⁹ and to the categories of static, dynamic, and early active rehabilitation as detailed by Sameem et al⁶⁰ in their systematic review. Furthermore, comparable grip strength^{45,47,48,50,51,53,54} and an earlier RTW have been found with RM management.^{44–46,49} Compared with RM, a similar percentage of patients were lost to follow-up.^{45,46,50–54} Orthosis wear time for these other programs are similar to RM ET programs; however, therapist users of RM commented that the orthosis is less cumbersome and more functional and does seem to allow return to full-duty work sooner.^{3,5,9–11,19,21,31} Future comparison studies using standardized functional tests are certainly needed to support these observations.

Therapy management programs

Six therapy management programs reported on 226 patients who used the combined RME and wrist orthoses in ET zones IV–VII

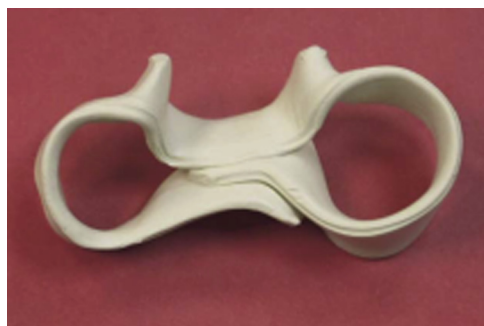

Fig. 12. Thermoplastic 3-finger relative motion extension orthosis for long finger sagittal band disruption. Reprinted from Ref.¹³ Copyright 2006, with permission from the American Society for Surgery of the Hand.

repairs^{3,5,11,16,30,31} and 7 programs use of only the RME orthosis for ET zones IV–VI repairs in 145 patients.^{9–11,16,18,19,21} The bulk of excellent and good results along with no reported tendon ruptures suggests commencement of RME for zones IV–VII ET repairs within the first postoperative week indicates that it is not only safe but also advised.^{3,5,9,11,19,21,30,31} Some authors modified the original RME program with an overnight resting orthosis^{9,21} for the prevention of extensor lag, edema, or unintentional wrist and finger flexion during sleep⁹ although the benefits have not been substantiated. An optimal duration of full-time wear of the RME orthosis with or without the wrist orthosis has not been identified; however, between 4 and 6 weeks has not produced tendon rupture or overwhelming stiffness^{3,5,9–11,16,18,19,21,31} Some authors have extended wear time or created a weaning period most often to address an extension lag^{11,21} or to protect the healing tendon during functional activities.^{3,9,10} Modification of the original RME or ICAM guidelines for discontinuing the orthosis or provisions such as discharging the orthosis at certain time points provided there was no extension lag¹¹ did make the assessment of optimal wear time duration confusing. We endorse the use of the program guidelines to allow clinicians to tailor the program to the needs of each patient.

There are few studies documenting the results of conservative management of SB injuries, and these consist of single cases or small case series^{13,61–67} and a retrospective review.²² Although the studies are few in number, conservative management of SB injuries has been recognized as an acceptable first line of treatment.^{13,22,63,64} Consistent with the time frames given in the RM studies by Catalano et al¹³ and Peelman et al,²² others have used an orthotic wear time of 3–8 weeks^{13,61–66}; with time extended if pain or slight subluxation of the tendon continued.^{22,62,65,66} Once

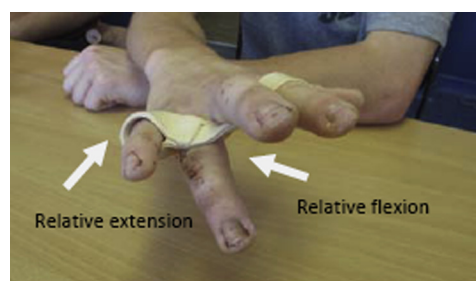


Fig. 13. Combined relative motion flexion (ring finger) and relative motion extension (small finger) orthosis.

type and thickness, and closure with Velcro or self-secured. If the relative MCPJ position is maintained, the design choices do not appear to matter, but this has not been studied. The 3-finger RME orthosis design was successfully used to conservatively manage SB injuries.^{13,22} Peelman et al²² felt that adherence improved when the hand-forearm-based orthosis was replaced by an RME orthosis. The versatility of the RM concept was illustrated by the single case report that combined RME and RMF into a 4-finger design single orthosis to manage 2 different ET injuries.³⁹ To better inform practice, future research is needed to examine efficacy, and designs for border digits, and patient comfort and adherence.

Orthosis and therapy management program terminology

Merritt³ has recommended that the term relative motion be used when either the concept or the orthosis is used. Agreement by authors to use either the name RME or RMF orthosis dependent on the position of the injured digit (or digits) MCPJ relative to its neighboring digit MCPJ is key for consistency in the literature. We propose that, for ease of comparison among studies, special notation be made when another orthosis, such as a wrist or resting orthosis is added. We also suggest that alternate names for therapy management programs using the RM concept and/or orthosis only make literature searches and crosstalk difficult.

Summary of scoping review findings

Table 3 is a summary of the findings of this scoping review with our hope to make this an easy reference from which surgeons and therapists can obtain the best available evidence.

Limitations

This scoping review was limited to English literature, adults, and returned a limited number of studies. There are no randomized controlled trials (RCTs) for RME or RMF. On the whole, most of the literature focused on the use of RM after zones IV-VII ET repair, with most in zone V. RM application for management of alternate conditions was restricted to small case studies. The significance of variables such as adding-on exercises to the RM program or how time after repair might influence outcome measurement is unclear, as is its use in immune-suppressed conditions and the nonadherent population. The brevity required of conference presentations and posters often made interpretation difficult. The gray literature search to find every conference presentation and poster was done with due diligence; however, some may not have been discovered.

Future research opportunities

The seemingly limitless application of the RM concept translates to the limitless research opportunities. There is need for RCTs in the use of RM for postoperative management of zone IV-VII ET injuries that examines the temporal components of orthosis wear, appropriate intervals to measure outcome, the degree of sufficient relative extension to protect the repair, zone by zone guidelines for when wrist immobilization is required, if an overnight resting orthosis is crucial, and specifics as to when daily activities/work/sport can be safely resumed. We are aware of 3 RCTs that are currently in data collection phase; RME and dynamic orthosis comparison,⁶⁸ a RME and immobilization comparison (personal communication between MH and Dershnee Devan), and a RME and MCPJ palmar blocking orthosis comparison.⁶⁹

Future research is indicated for conservatively and postsurgically RME-managed SB injuries. Categories to consider include

acute, subacute, and chronic, while separating the etiology into traumatic, atraumatic, or the rheumatoid population.

Effectiveness of RMF in the management of acute and chronic boutonniere, central slip repair, interosseous tears, and unexplained hand pain shows promise yet implores comparative studies. Case by case studies may provide a foundation to understand how to return fingers with extension lags or stiffness to function. Perhaps future evidence may lead to acceptance of RMF orthosis as an alternative approach for management of flexor tendon or digital nerve repairs.

Conclusion

Although RM is widely used, evidence level is low in the post-surgical management of zones IV-VII ET repairs, conservative management of SB injury, and as an exercise orthosis. This scoping review has identified factors essential for future research to improve the level of evidence for RM management of ET and SB injuries. Higher level evidence is also required for the emerging areas for which RM has also been used: acute and chronic boutonniere injuries, interosseous muscle tears, hand pain of unknown origin, and flexor tendon and digital nerve repairs.

Acknowledgments

The authors thank and acknowledge the Austin Health Hand Therapy team: Belynda Angell, Renée Bartlett, Jennifer Cassidy, Melanie Fischer, and David Jacobs; without them, the SEQES would not be done. They are also thankful to their 6 expert consultants Dr Donald Lalonde, Dr Wyndell Merritt, Maureen Hardy, Amanda Higgins, Sandy Robinson, and Gwendolyn van Strien for their valuable insights.

Their appreciation to Helen Baxter, Clinical Librarian Austin Health, who kindly assisted in compiling the database search strategies. Thank you is also extended to Associate Professor Ted Brown who assisted the understanding of scoping reviews. Foremost, finally, they would like to thank the patients who participated in the RM studies.

References

- Merritt WH. What's in a name? "ICAM" versus "relative motion" splints: what should we call these immediate active motion splints? *Hand Surg Q Fall*. 2012; 8.
- Robinson S. What is ICAM? *ASHT Times*. 2011;17(2):4–5.
- Howell JW, Merritt WH, Robinson SJ. Immediate controlled active motion following zone 4-7 extensor tendon repair. *J Hand Ther*. 2005;18(2):182–190.
- Rosenblum NI, Robinson SJ. Advances in flexor and extensor management. In: Moran C, ed. *Hand Rehabilitation*. New York, NY: Churchill Livingstone; 1986: 17–44.
- Robinson SJ, Rosenblum NI, Merritt WH. A new splint design for immediate active motion following extensor tendon repair. Paper presented at: American Society of Hand Therapists (ASHT) Conference. February 14th - 16th, 1986; New Orleans, LA.
- Sharma JV, Liang NJ, Owen JR, Wayne JS, Isaacs JE. Analysis of relative motion splint in the treatment of zone VI extensor tendon injuries. *J Hand Surg Am*. 2006;31(7):1118–1122.
- Chung B, Thanik V, Chiu DTW. Relative motion flexion splinting for flexor tendon repairs: proof of concept. Paper presented at: American Association for Hand Surgery (AAHS) Annual Meeting; January 21st - 24th, 2015; Bahamas.
- Merritt WH. Relative motion splint: active motion after extensor tendon injury and repair. *J Hand Surg Am*. 2014;39(6):1187–1194.
- Hirth MJ, Bennett K, Mah E, et al. Early return to work and improved range of motion with modified relative motion splinting: a retrospective comparison with immobilization splinting for zones V and VI extensor tendon repairs. *Hand Ther*. 2011;16(4):86–94.
- Burns MC, Derby B, Neumeister MW. Wyndell Merritt immediate controlled active motion (ICAM) protocol following extensor tendon repairs in zone IV-VII: review of literature, orthosis design, and case study—a multimedia article. *Hand (N Y)*. 2013;8(1):17–22.

11. Svens B, Ames E, Burford K, Caplash Y. Relative active motion programs following extensor tendon repair: a pilot study using a prospective cohort and evaluating outcomes following orthotic interventions. *J Hand Ther.* 2015;1(28): 11–19.
12. Merritt WH, Howell JW, Tune R, Saunders S, Hardy M. Achieving immediate active motion by using relative motion splinting after long extensor repair and sagittal band ruptures with tendon subluxation. *Operat Tech Plast Reconstr Surg.* 2000;7(1):31–37.
13. Catalano 3rd LW, Gupta S, Ragland 3rd R, Glickel SZ, Johnson C, Barron OA. Closed treatment of nonrheumatoid extensor tendon dislocations at the metacarpophalangeal joint. *J Hand Surg.* 2006;31(2):242–245.
14. Lalonde DH. Advances in extensor and flexor tendon injury management. Paper presented at: 9th Triennial Congress of the International Federation of Societies for Hand Therapy (IFSHT). March 4th - 8th, 2013; New Delhi, India.
15. Robinson S, Gyovai J, Howell J. The versatility of the immediate controlled active motion yoke (ICAM)—proceedings of the ASHT 26th Annual Meeting. *J Hand Ther.* 2004;17(1):78–79.
16. Berry N, Tonozzi J, Neumeister M. AAHS concurrent scientific paper session B. Analysis of limited Wyndell-Merritt splint for extensor tendon injuries to hand immobilization. *Hand.* 2008;3(2):170.
17. Saldana MJ. Early relative motion rehabilitation of proximal extensor tendon lacerations using the “Wyndell Merritt” splint. Paper presented at: American Association for Hand Surgery (AAHS) Annual Meeting. January, 1997; Phoenix, AZ.
18. Izadpanah A, Abrams M, Murray K, Hayakawa T, Iskur A. Modified Merritt splint in zone IV, zone V and distal zone VI extensor tendon injuries: nine years rehabilitation experience in a single center. Poster presentation at: American Association for Hand Surgery (AAHS) Annual Meeting. January 21st - 24th, 2015; Paradise Island, Bahamas.
19. Turner S. An audit of the use of the Merritt yoke relative motion splint for extensor tendon repair. Paper presented at: British Association of Hand Therapists (BAHT) Annual Conference. November 20th - 21st, 2015; Liverpool, England.
20. Thomas D, Moutet F, Guinard D. Postoperative management of extensor tendon repairs in zones V, VI, and VII. *J Hand Ther.* 1996;9(4):309–314.
21. Retallack L. A review of the effectiveness of the border digit splints in the treatment of extensor tendon repairs in zone V & VI [Diploma]: Diploma, Occupational Therapy, Curtin University of Technology, Perth, Western Australia; 2002.
22. Peelman J, Markiewitz A, Kiefhaber T, Stern P. Splintage in the treatment of sagittal band incompetence and extensor tendon subluxation. *J Hand Surg Eur Vol.* 2015;40(3):287–290.
23. AHTA hand & upper limb orthosis/splint schedule. Australian Hand Therapy Association (AHTA) newsletter. January-March 2012.
24. Author information pack. *Journal of Hand Therapy.* 2014.
25. Arksey H, O'Malley L. Scoping studies: towards a methodological framework. *Int J Soc Res Methodol.* 2005;8(1):19–32.
26. McKinstry C, Brown T, Gustafsson L. Scoping reviews in occupational therapy: the what, why, and how to. *Aust Occup Ther J.* 2014;61:58–66.
27. Levac D, Colquhoun H, O'Brien KK. Scoping studies: advancing the methodology. *Implement Sci.* 2010;5:69.
28. Howick J, Chalmers I, Glasziou P, et al. The 2011 Oxford CEBM Levels of Evidence (introductory document).
29. Hirth MJ. A single case study of relative motion extension splinting & relative motion flexion splinting. Paper presented at: American Association for Hand Surgery (AAHS) Annual Meeting. January 8th - 11th, 2014; Kauai, HI.
30. Altobelli GG, Conneely S, Haufler C, Walsh M, Ruchelsman DE. Outcomes of digital zone IV and V and thumb zone TI to TIV extensor tendon repairs using a running interlocking horizontal mattress technique. *J Hand Surg Am.* 2013;38(6):1079–1083.
31. Blakeway M. New directions for extensor tendon management: the immediate controlled active motion (ICAM) regime—a case report. Poster presentation at: 9th Triennial Congress of the International Federation of Societies for Hand Therapy (IFSHT). March 4th - 8th, 2013; New Delhi, India.
32. Howell JW, Hirth MJ. Tips and tricks for using relative motion splinting for extensor tendon injuries. Paper presented at: 9th Triennial Congress of the International Federation of Societies for Hand Therapy (IFSHT). March 4th - 8th, 2013; New Delhi, India.
33. Lalonde D. *Wide Awake Hand Surgery.* 1st ed. Boca Raton, FL: CRC Press; 2016.
34. Higgins A. Relative motion flexion and extension splints. Paper presented at: American Association for Hand Surgery (AAHS) Annual Meeting. January 8th - 11th, 2014; Kauai, Hawaii.
35. Howell JW, Peck F. Rehabilitation of flexor and extensor tendon injuries in the hand: current updates. *Injury.* 2013;44(3):397–402.
36. Minchin K. “Soft yoke” to replace thermoplastic yoke for ICAM protocol. *AHTA Newsletter.* 2014;(98):46.
37. Lalonde DH. ASHT invited speech—how the wide awake approach is changing hand surgery and hand therapy: Inaugural AAHS sponsored lecture at the ASHT meeting, San Diego, 2012. *J Hand Ther.* 2013;26(2): 175–178.
38. Howell JW, Merritt WH. Extensor tendon repair and management with immediate controlled active motion. Paper presented at: American Association for Hand Surgery (AAHS) Annual Meeting. January 11th - 14th, 2006; Tucson, AZ.
39. DeMott L, Mock M, Flinn S. Effects of relative motion orthoses and re-direction exercises for extensor lag following proximal phalanx fractures; a case series report. Poster presentation at: American Society of Hand Therapists (ASHT) Conference. October 8th - 11th, 2015; Denver, CO.
40. Colditz J. Active redirection instead of passive motion for joint stiffness. *ASHT Times.* 2014;21(3):6–9.
41. MacDermid JC. An introduction to evidence-based practice for hand therapists. *J Hand Ther.* 2004;17(2):105–117.
42. Kleinert HE, Verdan C. Report of the Committee on Tendon Injuries (International Federation of Societies for Surgery of the Hand). *J Hand Surg Am.* 1983;8(5 pt 2):794–798.
43. Miller H. Repair of severed tendons of the hand and wrist; statistical analysis of 300 cases. *Surg Gynecol Obstet.* 1942;75:693–698.
44. Browne Jr EZ, Ribik CA. Early dynamic splinting for extensor tendon injuries. *J Hand Surg Am.* 1989;14(1):72–76.
45. Bruner S, Wittemann M, Jester A, Blumenthal K, Germann G. Dynamic splinting after extensor tendon repair in zones V to VII. *J Hand Surg Br.* 2003;28(3):224–227.
46. Khandwala AR, Webb J, Harris SB, Foster AJ, Elliot D. A comparison of dynamic extension splinting and controlled active mobilization of complete divisions of extensor tendons in zones 5 and 6. *J Hand Surg Br.* 2000;25(2): 140–146.
47. Kitis A, Ozcan RH, Bagdatli D, Buker N, Kara IG. Comparison of static and dynamic splinting regimens for extensor tendon repairs in zones V to VII. *J Plast Surg Hand Surg.* 2012;46(3-4):267–271.
48. Mowlavi A, Burns M, Brown RE. Dynamic versus static splinting of simple zone V and zone VI extensor tendon repairs: a prospective, randomized, controlled study. *Plast Reconstr Surg.* 2005;115(2):482–487.
49. Sylaidis P, Youatt M, Logan A. Early active mobilization for extensor tendon injuries. The Norwich regime. *J Hand Surg Br.* 1997;22(5):594–596.
50. Bulstrode NW, Burr N, Pratt AL, Grobbelaar AO. Extensor tendon rehabilitation a prospective trial comparing three rehabilitation regimes. *J Hand Surg Br.* 2005;30(2):175–179.
51. Hall B, Lee H, Page R, Rosenwax L, Lee AH. Comparing three postoperative treatment protocols for extensor tendon repair in zones V and VI of the hand. *Am J Occup Ther.* 2010;64(5):682–688.
52. Slater Jr RR, Bynum DK. Simplified functional splinting after extensor tenorrhaphy. *J Hand Surg Am.* 1997;22(3):445–451.
53. Ip WY, Chow SP. Results of dynamic splintage following extensor tendon repair. *J Hand Surg Br.* 1997;22(2):283–287.
54. Newport ML, Blair WF, Steyers Jr CM. Long-term results of extensor tendon repair. *J Hand Surg Am.* 1990;15(6):961–966.
55. Purcell T, Eadie PA, Murugan S, O'Donnell M, Lawless M. Static splinting of extensor tendon repairs. *J Hand Surg Br.* 2000;25(2):180–182.
56. Chow JA, Dovel S, Thomes LJ, Ho PK, Saldana J. A comparison of results of extensor tendon repair followed by early controlled mobilisation versus static immobilisation. *J Hand Surg Br.* 1989;14(1):18–20.
57. Eissens MH, Schut SM, van der Sluis CK. Early active wrist mobilization in extensor tendon injuries in zones 5, 6, or 7. *J Hand Ther.* 2007;20(1):89–91.
58. Hung LK, Chan A, Chang J, Tsang A, Leung PC. Early controlled active mobilization with dynamic splintage for treatment of extensor tendon injuries. *J Hand Surg Am.* 1990;15(2):251–257.
59. Talsma E, de Haart M, Beelen A, Nolle F. The effect of mobilization on repaired extensor tendon injuries of the hand: a systematic review. *Arch Phys Med Rehabil.* 2008;89(12):2366–2372.
60. Sameem M, Wood T, Ignacy T, Thoma A, Strumas N. A systematic review of rehabilitation protocols after surgical repair of the extensor tendons in zones V-VIII of the hand. *J Hand Ther.* 2011;24(4):365–372. quiz 373.
61. Araki S, Ohtani T, Tanaka T. Acute dislocation of the extensor digitorum communis tendon at the metacarpophalangeal joint. A report of five cases. *J Bone Joint Surg Am.* 1987;69(4):616–619.
62. Capo JT, Shamian B, Rossy W, Hashem J. Closed sagittal band injury due to low energy trauma. *Am J Orthop.* 2012;41(8):374–377.
63. Carroll CT, Moore JR, Weiland AJ. Posttraumatic ulnar subluxation of the extensor tendons: a reconstructive technique. *J Hand Surg Am.* 1987;12(2): 227–231.
64. Inoue G, Tamura Y. Dislocation of the extensor tendons over the metacarpophalangeal joints. *J Hand Surg Am.* 1996;21(3):464–469.
65. Rayan GM, Murray D. Classification and treatment of closed sagittal band injuries. *J Hand Surg Am.* 1994;19(4):590–594.
66. Ritts GD, Wood MB, Engber WD. Nonoperative treatment of traumatic dislocations of the extensor digitorum tendons in patients without rheumatoid disorders. *J Hand Surg Am.* 1985;10(5):714–716.
67. Willekens I, Kichouh M, Boulet C, De Maeseener M, Clarys JP, de Mey J. Ultrasound follow-up of posttraumatic injuries of the sagittal band of the dorsal hood treated by a conservative approach. *Eur J Radiol.* 2015;84(2): 278–283.
68. Buhler M, Abbott H, Jones DG, Chin M, Woodside J. Is relative motion extension splinting non-inferior and more cost-effective compared to dynamic extension

- splinting for extensor tendon repair in zone V and VI: a randomised controlled trial. Australian and New Zealand Clinical Trials Registry (ANZCTR): ACTRN12615000425594.
69. Collocott S, Foster M, Zeng I, Myhr H. Can relative motion extension splinting provide an earlier return to hand function than a controlled active motion protocol after extensor tendon repair in zone V and VI? A prospective randomised clinical trial. Australian and New Zealand Clinical Trials Registry (ANZCTR): ACTRN12615000043538.
70. Ishiguro T. Tension-reduced early mobilization for reconstruction of ruptured extensor digitorum communis tendons. *J Jap Soc Surg Hand*. 1989;6(3):179–182.
71. van Strien G. *Conservative Treatment of the Stiff PIP Joint After Dislocation (and Dupuytren)*. Arnhem, The Netherlands: Paper presented at: Dutch Society for Hand Surgery and Hand Therapy; November 2, 2013.
72. van Strien G. Relative motion splints: a simple solution to many hand problems. Paper presented at: American Association for Hand Surgery (AAHS) Annual Meeting. January 8th - 11th, 2014; Kauai, Hawaii.

Appendix

Appendix A

Excluded studies

Author/s (location) year Document type	Title	Injuries treated	Aims	Summary	Level of evidence	Reason for exclusion
Ishiguro et al ¹⁰ (Japan) 1989 Scientific article	Tension-reduced early mobilization for reconstruction of ruptured extensor digitorum communis tendons	ET ruptures wrist level <i>n</i> = 14 fingers: 5 RA, 1 Kienbock, 1 OA	Described taping technique to reduce tension on repair	<i>RME</i> : Tape. Tension on tendon is reduced by taping repaired finger dorsally and crossed over adjacent finger 6-8 wk <i>ROM</i> : All MCPJ had equal or similar extension to the adjacent MCPJ; 83° MCPJ mean flexion	IV	Abstract and diagram in English. Body of article in Japanese
Thomas et al ²⁰ (France) 1996 Scientific article	Postoperative management of extensor tendon repairs in zones V, VI, and VII	Partial and isolated ET index and small fingers' lacerations	Documented the Grenoble protected mobilization method	<i>RME</i> : Thermoplastic orthosis with affected digit in extension in relation to adjacent digits; applied Frere 3-finger rule to determine which fingers are splinted. <i>RME</i> orthosis wear 30-45 d Data grouped according to type treatment; most data combined	IV	Some data included, RM data were pooled with non-RM data
Saldana ¹⁷ (United States) 1997 Conference presentation	Early relative motion rehabilitation of proximal extensor tendon lacerations using the "Wyndell Merritt" splint	Zone IV-VII ET	Compared RME with dynamic orthosis program	<i>RME</i> and wrist orthoses (per Dr Merritt IFSSH meeting presentation in 1995, Finland) 4/52 wear <i>ROM</i> : Over time, both methods yielded excellent results, RME less stiff and functional earlier No quantitative data available <i>Preference</i> : RME more user friendly RME orthosis referred to as the Wyndell Merritt splint	IV	Personal (JH) communication with Saldana (retired), said more stiffness, and dynamic group had 3/25 ruptures. Resulted in protocol switch to RME
Merritt et al ¹² (United States) 2000 Scientific article	Achieving immediate active motion by using relative motion splinting after long extensor repair and sagittal band ruptures with tendon subluxation	Zones IV-VII ET SB disruption with ET subluxation	Outlined rationale, indications, and RME program	<i>RME</i> : Injured MCPJ 10°-15° relative extension; if either border digit repaired, the central digits are in less relative MCPJ extension than the border digits <i>Wrist</i> : 25° extension <i>RME and wrist orthoses</i> : Both orthoses worn 3-4/52, RME-only 4-6/52 <i>RTW and function</i> : Full hand use in the orthoses. RTW protocol individualized Includes previously presented information on 180 patients with 1-3 lacerated tendons over a 10-y period and a case study on extensor subluxation due to SB disruption	IV	More thorough data in the study by Howell et al ³ for ET repair Limited data on the SB case study
Robinson et al ¹⁵ (United States) 2004 Conference proceedings	The versatility of the immediate controlled active motion yoke (ICAM)	C5-C6 discectomy, MC fracture with lag, ulnar nerve palsy, RA digit misalignment, Parkinson,	Demonstrated alternative clinical uses for "ICAM yoke"	<i>RME and RMF</i> : Functional splint (6 cases), exercise splint (2 cases) <i>ROM</i> : Exercise cases gained	IV	Limited data

(continued on next page)

Appendix A (continued)

Author/s (location) year Document type	Title	Injuries treated	Aims	Summary	Level of evidence	Reason for exclusion
published in scientific journal		PIPJ stiffness, decreased MCPJ flexion		ROM <i>Alignment, balance, and function:</i> Documented in before/after photographs <i>Compliance:</i> Attributed high compliance to small and comfortable splint that allows function Coined term permanent adaptive splint to improve MCPJ alignment, balance, and function		
Sharma et al ⁶ (United States) 2006 Scientific article	Analysis of relative motion splint in the treatment of zone VI extensor tendon injuries	Zone VI ET index, long and ring fingers	Biomechanical analysis of ET strain with or without RME orthosis and intact/repared tendon	<i>RME:</i> Thermoplastic 15° relative MCPJ extension <i>Wrist:</i> 25° extension fixed in testing apparatus <i>Findings:</i> RME reduced strain on intact and repaired zone VI long finger EDC, without RME orthosis permanent stretch to repair Technically difficult to evaluate zone V Recommend future studies in ET zones IV-VII and less wrist extension	V	Cadaver study
Lalonde ¹⁴ (Canada) 2013 Conference presentation	Advances in extensor and flexor tendon injury management	ET repair and graft SB injuries Boutonniere, interosseous tears, digital nerve and flexor tendon repairs Loss of PIPJ flexion and extension	Presented advances in tendon injury management including WALANT	<i>RME:</i> Original design, thermoplastic and Velcro. <i>ET:</i> wrist orthosis not always needed <i>RTW:</i> ET case study returned to work 2/52; 3-4 d postoperatively for many; need for wrist orthosis varies <i>Acute boutonniere:</i> When boutonniere corrected with RMF orthosis—wear daytime for 8/52 combined with overnight PIP extension orthosis. When boutonniere is not corrected, serial cast until PIPJ actively and passively extends and complete DIP active flexion; then follow original RMF guidelines <i>RMF success—boutonniere deformity:</i> Case study of 83 y with video documentation of progress <i>RMF success—interosseous muscle tear:</i> Pain gone with RMF orthosis; previous treatments failed	IV	Limited data
Howell and Hirth ³² (USA and Australia) 2013 Conference presentation	Tips and tricks for... using relative motion splinting for extensor tendon injuries	Zones IV-VII ET, SB injuries, boutonniere Extensor lag, stiff PIPJ	Shared RM orthosis tips and tricks for fabrication, how to	<i>RME and RMF:</i> Thermoplastic self-securing and with securing Velcro strap designs	IV	Duplicate data given on long ETs

		C5-C6 discectomy, maligned MC fracture and RA imbalances	improve outcomes and unique uses	<p><i>ET</i>: Recommended tailoring program to the patient. Wear full time 4/52. Immediate functional hand use.</p> <p><i>Boutonniere</i>: Wear RMF orthosis 6-8/52; use hand functionally (expert opinion only)</p> <p><i>MCPJ extensor lag</i>: case study—RME orthosis worn full time 2/52</p> <p><i>PIPJ stiffness</i>: Case study—RME exercise orthosis worn 4-6 times per day to regain PIPJ flexion</p> <p><i>Alignment</i>: Before/after photographs; permits function. Orthosis worn during functional tasks at patients' discretion</p>	IV	Limited data for other conditions
van Strien ⁷¹ (The Netherlands) 2013 Conference presentation	Conservative treatment of stiff PIP joint after dislocation (and Dupuytren's)	35° PIPJ flexion contracture	Presented RM to treat stiff PIPJ	<p><i>RMF</i>: Wear orthosis as much as possible to encourage PIPJ extension</p> <p><i>ROM</i>: 3 months serial cast to resolve 35° PIPJ flexion contracture plus 3 months RMF orthosis to support active PIPJ extension</p>	IV	Limited data
Higgins ³⁴ (Canada) 2014 Conference presentation	Hands-on therapists development workshop	ET zones IV-VII SB injuries Acute boutonniere	Provided workshop on RME/RMF orthoses	<p><i>RME</i>: 15° relative MCPJ extension for 6/52, wrist orthosis initial 3-4/52; partial lacerations RME orthosis only; use for function immediately</p> <p><i>SB</i>: Cases illustrated use of RM postoperatively and nonsurgically: Suggested minimum 6/52 orthosis wear</p> <p><i>Boutonniere</i>: RMF involved digit 15° more MCPJ flexion than adjacent MCPJ for 6/52</p> <p>Tabulated Merritt's/Lalonde's RMF cases zone III—Merritt: acute open (4), acute closed (9), late 3-6/52 closed injury (4), chronic boutonniere > 2 mo (13), and Lalonde (15)</p>	IV	Limited data
van Strien ⁷² (The Netherlands) 2014 Conference presentation	Relative motion splinting for acute and chronic boutonniere	Acute and chronic boutonniere	Outlined RMF management of boutonniere	<p><i>RMF</i>: Information presented from Dr Lalonde's presentation at IFSHT, India 2013¹⁴</p> <p>Serial cast until full passive PIPJ extension then RMF orthosis; RMF case study</p> <p><i>Tips</i>: Emphasize PIPJ extension more than flexion</p>	IV	Limited data

(continued on next page)

Appendix A (continued)

Author/s (location) year Document type	Title	Injuries treated	Aims	Summary	Level of evidence	Reason for exclusion
Merritt ⁸ (United States) 2014 Scientific article	Relative motion splint: Active motion after extensor tendon injury and repair	Zones IV–VII ET, SB, boutonniere, CUS, flexor tendon repair RM for the stiff PIPJ after trigger, release, and intrinsic tightness	Outlined RM rationale and conditions for RM orthoses; pearls and pitfalls	<i>RME and RMF</i> : 15°–20° relative MCPJ extension or flexion to other MCPJs <i>ET repair</i> : RME and wrist orthoses: both 3/52, stop wrist orthosis 3/52, wear only RME <i>SB</i> : RME: Wear for 6/52 <i>Boutonniere</i> : RMF only 6/52 if full passive PIPJ extension. Video documentation in progress. <i>CUS</i> : Pan type relative extension 6/52 with wrist included and forearm in supination 3/52 <i>Flexor tendon</i> : RMF to protect FDP/S repair with full motion at 3 wk postoperatively <i>Stiffness</i> : RME and RMF: thermoplastic self-securing and thermoplastic Velcro strap designs presented; 15°–20° relative extension or flexion <i>RMF</i> : MCPJ positioned in 70°–80° flexion; thermoplastic <i>Wrist</i> : 30° extension in test apparatus <i>Results</i> : No elongation of tendon after flexion/extension cycling; proof-of-concept RMF may offer protection after FDP zone III repair	IV	Limited data
Chung ⁷ (Canada) 2015 Conference presentation	Relative motion flexion splinting for flexor tendon repairs: Proof of concept	Zone III long finger FDP repair—cadaver	Evaluated RMF for zone III FDP repair	<i>RMF</i> : MCPJ positioned in 70°–80° flexion; thermoplastic <i>Wrist</i> : 30° extension in test apparatus <i>Results</i> : No elongation of tendon after flexion/extension cycling; proof-of-concept RMF may offer protection after FDP zone III repair	V	Cadaver study
Lalonde ³³ (Canada) 2016 Book	Wide awake hand surgery	ET repair, acute and postsurgical SB injury, acute and chronic boutonniere, central slip injury, interosseous tears, flexor and extensor lag PIPJ, hand pain, digital nerve repairs	Presents advantages of WALANT for ET repair of the finger (chapter 35), ET repair of the hand (chapter 36), and lacerated nerves (chapter 40)	<i>RME</i> : 3-finger and 4-finger designs; thermoplastic with and without Velcro Video documentation of patient progress (showing motion) after ET repair, central slip injury, and acute and chronic boutonniere Video clips of intraoperative decision making; assessing tension/strain on the repaired ET with RME to determine if wrist immobilization is also needed, and assessing suitability of RMF after digital nerve repair Video demonstration of the pencil test simulating RME and RMF to evaluate patients with hand problems	IV	Limited data

ET = extensor tendon; RA = rheumatoid arthritis; OA = osteoarthritis; RME = relative motion extension; ROM = range of motion; MCPJ = metacarpophalangeal joint; RM = relative motion; IFSH = International Federation of Societies for Surgery of the Hand; SB = sagittal band; RTW = return to work; MC = metacarpal; PIPJ = proximal interphalangeal joint; ICAM = immediate controlled active motion; RMF = relative motion flexion; EDC = extensor digitorum communis; WALANT = Wide-Awake Local Anaesthesia No Tourniquet; DIP = distal interphalangeal; IFSHT = International Federation of Societies for Hand Therapy; CUS = caput ulnae syndrome; FDP = flexor digitorum profundus.

Appendix B

Expert opinion pieces

Author/s (location) year Document type	Title	Injuries treated	Aims	Summary	Level of evidence	Reason for exclusion
Robinson ² (United States) 2011 Newsletter publication	What is ICAM?	Zones IV–VIII ET	Shared ICAM information	<i>RME</i> : Injured MCPJ in relative extension Wrist: 20°–25° extension <i>RME and wrist orthoses</i> : Phase 1: 0–21 d both orthoses worn continuously; phase 2: 22–35 d RME orthosis only, add wrist orthosis for heavy tasks. Phase 3: 36–49 d RME orthosis only removed for exercises <i>RTW</i> : Many RTW in either the RME or both orthoses. Author did not recommend the neoprene RME in early phases because it does not seem to preserve protected position Dr Merritt and Dr Lalonde endorse: “relative motion extensor” or “relative motion flexor” orthoses	V Expert opinion	No data
Merritt ¹ (United States) 2012 Newsletter publication	What's in a name? “ICAM” versus “relative motion” splints: What should we call these immediate active motion splints?	Zones IV–VII ET Boutonniere, intrinsic and ET transfers, joint replacement, flexor tendons, and digital nerves	Clarified RM terminology	Dr Merritt and Dr Lalonde endorse: “relative motion extensor” or “relative motion flexor” orthoses	V Expert opinion	No data
Howell and Peck ³⁵ (United States and UK) 2013 Scientific article	Rehabilitation of flexor and extensor tendon injuries in the hand: Current updates	ET repairs Boutonniere	Defined concepts relevant to decisions made for tendon rehabilitation	<i>RME</i> : ET repairs zones IV–VII; except if all EDC, EIP, and EDM involved, decision-making algorithm; tendon excursion, repair specifics, safe mobilization and measuring ROM suggestions Decision algorithm aligned with healing phases for RMF in management of ET zone III	V Expert opinion	No data
Lalonde ³⁷ (Canada) 2013 Scientific article	How the wide awake approach is changing hand surgery and hand therapy	ET repairs SB injuries Interosseous tears, digital nerve repairs, and boutonniere Flexion and extension lags	Discussed RM in the context of WALANT and benefits of intraoperative assessment	<i>RME and RMF</i> : Thermoplastic with or without Velcro strap. Two designs: 3-finger and original RME designs. WALANT permits assessment of repair and need for wrist orthosis <i>SB</i> : Single-case study, long finger involved; used original RME <i>Boutonniere</i> : When active PIP extension in RMF orthosis results, no other orthosis required. Serial casting/static orthosis if PIPJ extensor lag or PIPJ flexion contracture <i>Digital nerve repairs</i> : If during WALANT, RMF puts nerve on slack, permit active motion <i>Interosseous tears</i> : RMF orthosis effectively reduced pain and allowed RTW	V Expert opinion	No data
Minchin ³⁶ (Australia) 2014 Newsletter publication	“Soft yoke” to replace thermoplastic yoke for ICAM protocol	Single zone V ET repairs, stiff MCPJ and IPJs, minimize PIPJ and MCPJ extensor lags Reduced volar PIPJ subluxation in swan neck deformity	Shared clinical pearls in AHTA newsletter	<i>RME and RMF</i> : 6-mm thick neoprene loop secured by Velcro or soft yoke-type loop made of Fabrifoam, degree of relative position not stated	V Expert opinion	No data
Colditz ⁴⁰ (United States) 2014 Newsletter publication	Active redirection instead of passive motion for joint stiffness	Stiff hand	Discussed active redirection for joint stiffness	Active redirection: Blocking orthosis; waking hours or full time wear (severe stiffness) Coined term <i>active redirection</i> to redirect forces; used RM example	V Expert opinion	No data

ICAM = immediate controlled active motion; ET = extensor tendon; RME = relative motion extension; MCPJ = metacarpophalangeal joint; RTW = return to work; RM = relative motion; EDC = extensor digitorum communis; EIP = extensor indicis proprius; EDM = extensor digit minimi; ROM = range of motion; RMF = relative motion flexion; SB = sagittal band; WALANT = Wide-Awake Local Anaesthesia No Tourniquet; IPJs = interphalangeal joints; AHTA = Australian Hand Therapy Association.