

Flexor Tendon Injuries



Jin Bo Tang, MD

KEYWORDS

- Flexor tendon • Repair methods • Pulley release or venting • Early active motion
- Secondary surgeries

KEY POINTS

- Zone 2 flexor tendon repairs have evolved greatly over the past 3 decades.
- The key developments in zone 2 repairs are (1) use of strong core suture, typically 4- or 6-strand repairs, (2) venting the critical annular pulley judiciously to avoid compression to the repaired tendon, (3) ensuring slightly tensional repair to prevent gapping at the repair site, (4) performing a digital extension-flexion test to ascertain quality surgical repair, and (5) early partial range active motion to ensure tendon gliding but not overloading the repair site.
- I prefer direct repair of the very distal flexor tendon or in making the distal junction of the grafted tendon. In zone 2 and proximal zone 1, I use a 6-strand repair method, the M-Tang repair, in repairing the flexor tendons.
- A few recent evolutions have been reported by surgeons, which hold promise to be adopted by other hand surgeons: (1) using a strong core suture-only repair method, (2) venting the A3 together with A4 pulleys in case of need to sacrifice clinically insignificant tendon bowstringing for gain of range of active motion of the finger, and (3) a wide-awake surgical setting for tendon repair or tenolysis.

INTRODUCTION

Several recent articles have evaluated developments in flexor tendon repair and their contribution to progress toward reliable primary repair of the flexor tendons.¹⁻⁵ This article highlights the relevant anatomic and mechanical features, clinical methods, and essential elements in a reliable repair, then offers an overview of advancements in flexor tendon repair.

Zone 2 flexor tendon repairs have evolved greatly over the past 3 decades, and consequently, outcomes have changed dramatically since the last half of the twentieth century. Several major conceptual changes, and widespread use of some key surgical methods and postoperative motion protocols have helped to bring about the changes.⁶⁻¹⁷ Current key practices include

Using strong core sutures, typically 4- or 6-strand repairs

Judicious venting of the critical annular pulley
Ensuring that a slight tension is created by the repair to prevent gapping
Performing digital extension-flexion tests to confirm the quality of the surgical repair
Early partial range active motion to ensure tendon gliding without overloading the repair

Having the patient wide awake without use of a tourniquet during surgery represents an important advancement, allowing active motion of the tendon during surgery.^{11,12} Wide-awake surgery has also transformed how tenolysis and secondary tendon reconstruction are performed.

ANATOMIC AND MECHANICAL KEY POINTS

A unique feature of the flexor tendon anatomy is the presence of segmental annular pulleys in the digital area, with the A2 pulley over the proximal two-thirds of the proximal phalanx being the

Disclosure Statement: The author has nothing to disclose.

Department of Hand Surgery, The Hand Surgery Research Center, Affiliated Hospital of Nantong University, 20 West Temple Road, Nantong 226001, Jiangsu, China
E-mail address: jinbotang@yahoo.com

Clin Plastic Surg 46 (2019) 295-306

<https://doi.org/10.1016/j.cps.2019.02.003>

0094-1298/19/© 2019 Elsevier Inc. All rights reserved.

largest and strongest, and the A4 pulley over the midpoint of the middle phalanx being the second largest (**Fig. 1**). The annular pulleys serve to prevent tendon bowstringing during digital flexion. Although the A3 and A1 pulleys also perform this function, their role is less critical than the A2 and A4. Loss of integrity of any one of the pulleys alone has no marked functional consequence, although anatomically, minor tendon bowstringing occurs at the site of the loss.

The middle and distal parts of the A2 pulley (1.5–1.7 cm long in adult middle finger) and the A4 pulley (about 0.5 cm long) are the narrowest and most constricting to the flexor tendons. These sites become compressive to the repaired tendons because of postoperative tendon swelling. These narrow pulley sites may be incised to allow the repaired tendons to glide more freely.

Several factors affect the strength of repaired tendon:

- The number of suture strands across the repair sites—strength is roughly proportional to the number of core sutures
- The tension of repairs—most relevant to gap formation and stiffness of repairs
- The core suture purchase
- The types of tendon-suture junction—locking or grasping

The diameter of suture locks in the tendons—a small diameter of locks diminishes anchor power

The suture calibers (diameter)

The material properties of suture materials

The curvature of tendon gliding paths—the repair strength decreases as tendon curvature increases

The holding capacity of a tendon, affected by varying degrees of trauma and post-traumatic tissue softening

It must be realized that tendon curvature during finger flexion greatly affects the repair strength. A tendon under curvilinear tension is subjected to linear pulling and bending forces. Therefore, a repair in a tendon under a curvilinear load is weaker than that under a linear load; the repair strength decreases progressively as the curvature increases.^{18,19} Therefore, the repair fails more easily in the flexed finger, and when the finger moves to approach full flexion, a bent tendon is particularly prone to fail. This is the mechanical basis of current partial active finger flexion protocols and 1 reason why a full fist should be avoided in the initial a few weeks after surgery (**Table 1**).

Fig. 2 summarizes the breakdown of contributors of postoperative resistance to tendon gliding²⁰ that should be considered in planning

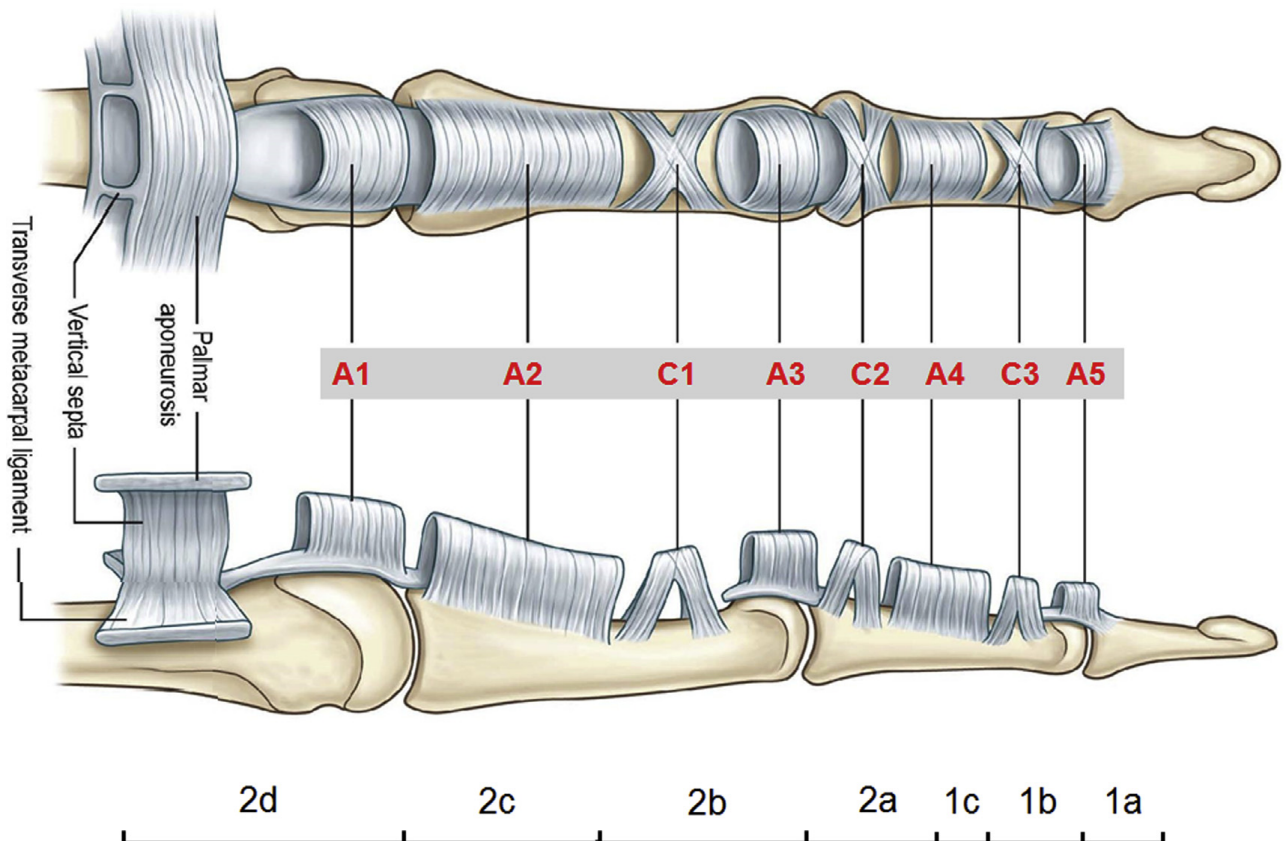


Fig. 1. Locations of the annular and cruciate pulleys of the fingers and the subdivisions of zone 1 and 2.

Table 1
Resistance to tendon gliding during active finger flexion in initial weeks of tendon healing

Active Flexion	Resistance to Tendon Gliding	Healing Tendons during Active Motion
None to mild	Low	Not easily disrupted
Mild to moderate	Low or moderately high	Not easily disrupted
Moderate to full	Very high	Easy to disrupt; should avoid such motion

and adjusting the active motion protocols. The safety margin of early active digital flexion can be enhanced by a strong surgical tendon repair or appropriately decompressing the tendon during surgery through releasing restricting pulleys, limiting the lengths of skin incisions, and minimizing the trauma to the tendon and sheath. After surgery, delicate adjustments in early active flexion to fit individual patients by a therapist or surgeon is also important.

PRIMARY AND DELAYED PRIMARY REPAIR

Nowadays most lacerated flexor tendons in the hand and forearm are repaired on the same day

of injury or a few days later. Primary repair indicates the end-to-end repair performed within 24 hours after tendon injury. When an experienced surgeon is not available on the day of injury, the repair can be deliberately delayed, and delayed primary repair is performed in a selective surgical setting. The delay usually has no adverse effects on outcomes, but in this period of delay, antibiotic use reduces the risk of infection of the wound. Delayed primary repair is the repair performed within 3 or even 4 weeks after injury. The end-to-end repair is often still possible 5 weeks after injury.

Zone 2 is the most complex and demanding and will be highlighted in the following section.

Exposure and Finding Tendon Ends in Zone 2

The tendons are exposed through a Bruner skin incision of 1.5 to 2 cm (Fig. 3), which is usually sufficient to expose the tendons. The author and colleagues keep the skin incision as limited as possible to decrease edema of the digit and resistance to tendon gliding after surgery. Retraction of the proximal tendon stump is common, especially in delayed primary repair. If the proximal flexor digitorum profundus (FDP) tendon end has not retracted far proximally, flexion of the metacarpophalangeal (MCP) or proximal interphalangeal (PIP) joints can bring the proximal end into the incision site.

If the proximal FDP tendon end retracts to the palm, I do not extend the incision to the palm,

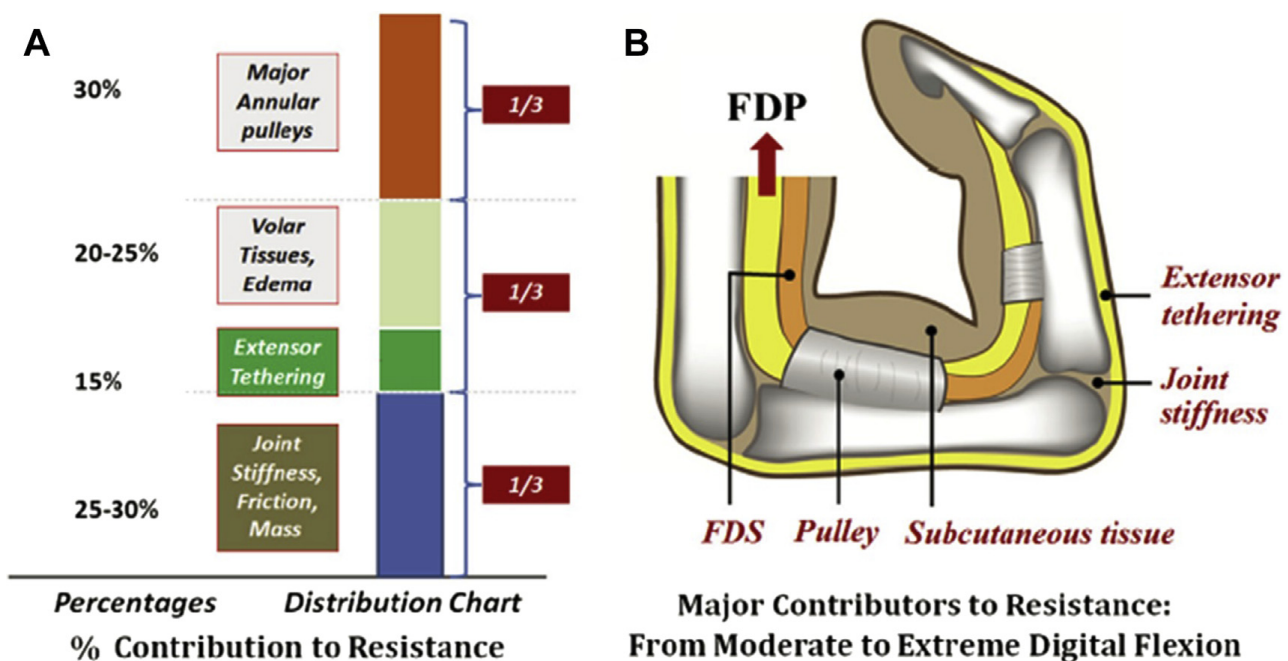


Fig. 2. The breakdown of contributors of postoperative resistance to tendon gliding. (A) Percentage contribution to the resistance. (B) Contributing factors. (From Wu YF, Tang JB. Tendon healing, edema, and resistance to flexor tendon gliding: clinical implications. *Hand Clin* 2013;29:167–78; with permission.)

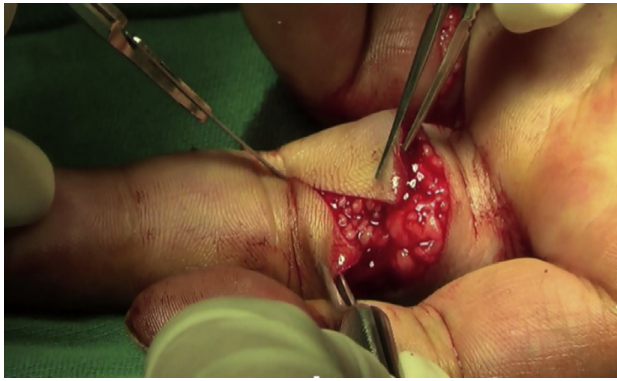


Fig. 3. A Bruner skin incision of 1.5 to 2 cm for exposure of the laceration site.

but instead make an additional incision in the distal palm. I can always find the retracted tendon end in the distal palm. From this small incision, the proximal tendon end is pushed distally within the synovial sheath bit by bit using 2 forceps (**Fig. 4**), like pushing a rope until the distal end is seen out of the distal opening in the sheath.

The forceps instrument is used to pull the exposed proximal end distally for about 1 cm. Then the finger is held in slight flexion; a 25-gauge needle is inserted at the base of the finger through the proximal tendon stump to hold the tendon during repair.

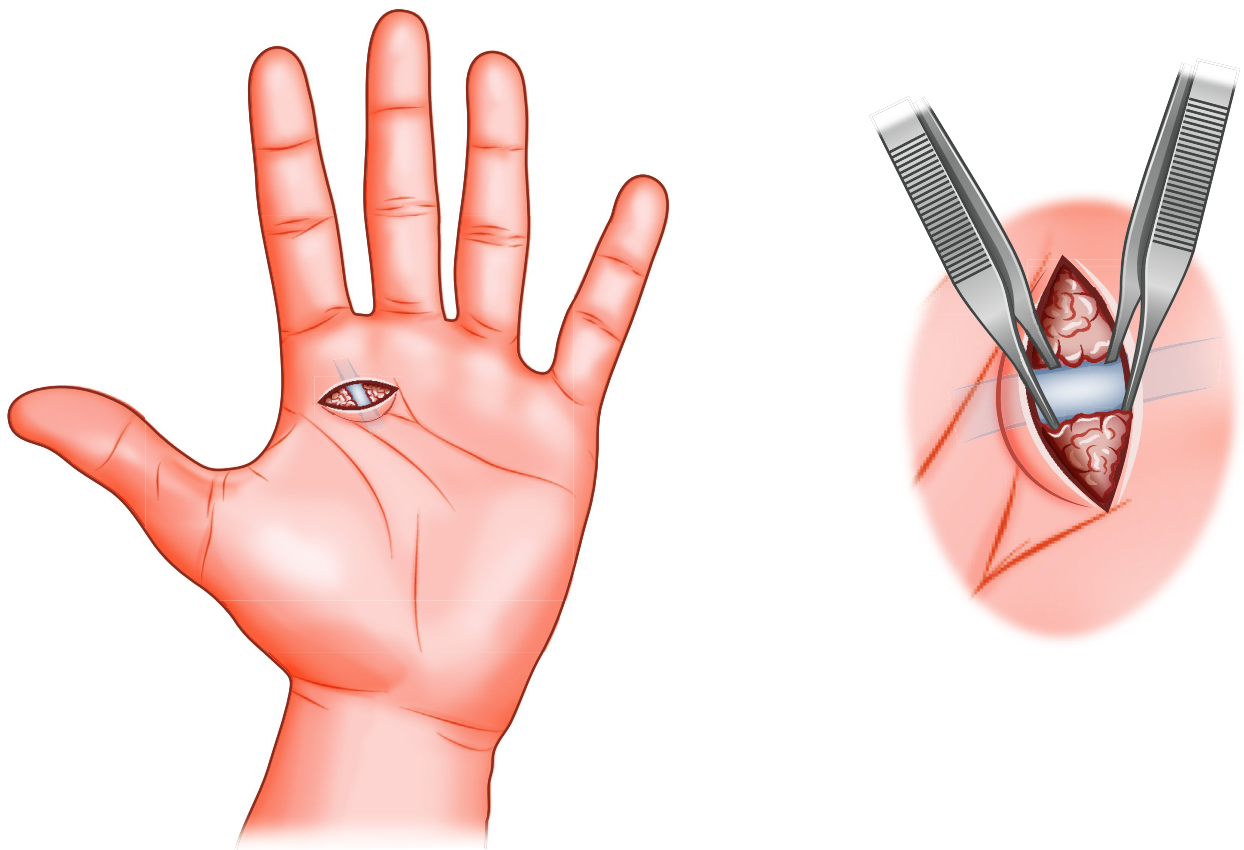


Fig. 4. Pushing the retracted FDP tendon with 2 forceps through a distal palm incision.

Surgical Repair Techniques

The tendon tissue at the cut ends is often ragged and should be conservatively trimmed with a scissors. Basic requirements of a tendon repair in primary repair of a flexor tendon are sufficient strength, smooth tendon gliding surface with fewer suture exposures, prevention of gapping of the repair site under tension, and easy to perform. Different configurations of the repairs may produce good outcomes given all the requirements are met. Surgeons in different centers use different multistrand repairs (**Fig. 5**).²¹ I use the 6-strand M-Tang repair method in the repair in zone 2 (**Fig. 6**). I then add a simple running peripheral suture or add 3 or 4 separated stitches sparsely over the volar and lateral aspects of the repair site with 6-0 nylon.

Methods of End-to-End Repair: Keys

There are 3 essential surgical keys of making a strong tendon repair. First, one must ensure core suture purchase of at least 0.7 to 1.0 cm to generate maximal holding power and a sufficiently large size (2 mm in diameter) of locks if a locking suture is used. Surgical repair strength decreases as the length of the purchase decreases. Tendon cut surfaces tend to soften after trauma. The repair

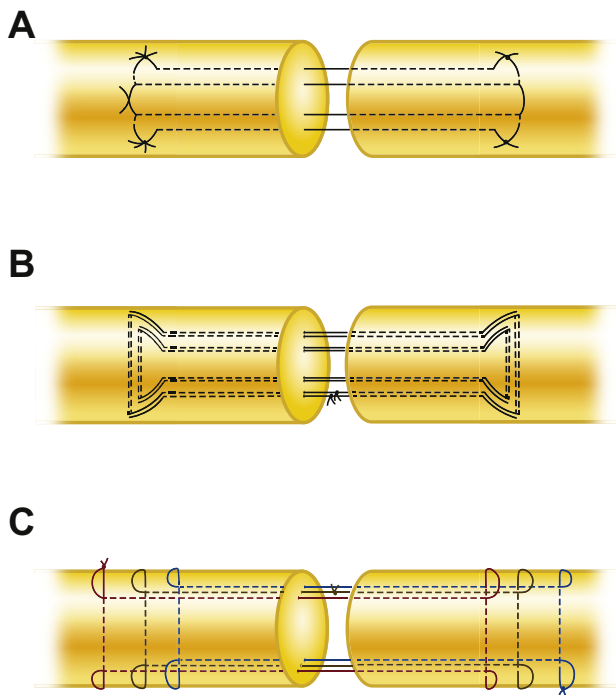


Fig. 5. Several multistrand core suture methods used by hand surgeons. (A) A 4-strand repair. (B) A 8-strand repair. (C) A 6-strand repair made from 3 groups (each in a different color) of the Kessler repair in asymmetric placement in 2 tendon stumps.

is at great risk of rupture if the suture purchase is short.

The second key in the repair is that certain tension across repair site should be maintained. To prevent gapping, it is important to ensure the repair has tension or a certain degree of bulkiness

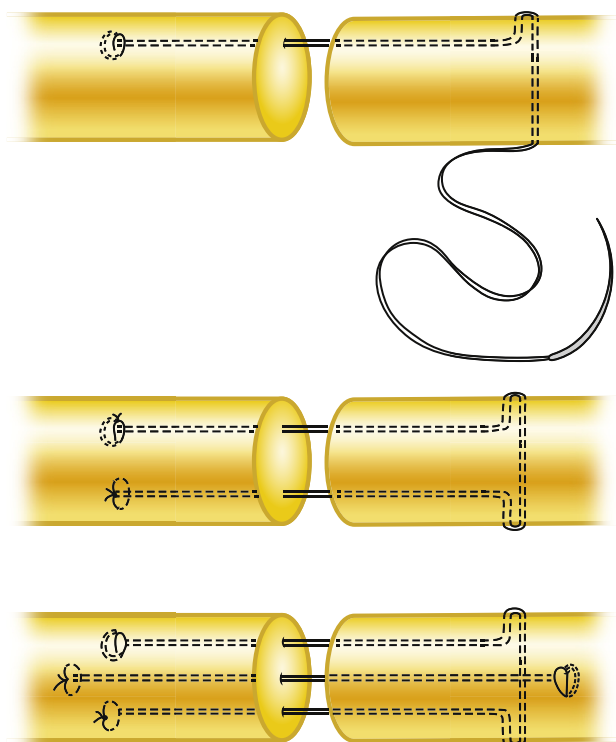


Fig. 6. The method of making a 6-strand M-Tang repair, which the author uses for the FDP and PFL repair.

that results in 10% to 20% shortening of the tendon parts encompassed by core sutures, or a 20% to 30% increase in the diameter of junction site of the 2 tendon ends (**Fig. 7**).²² A small amount of baseline tension would counteract the tension of the flexor muscles during resting or active motion. The repair site becomes more flattened once it is under the load of active digital flexion. Such degrees of bulkiness do not hamper tendon gliding with proper pulley venting.

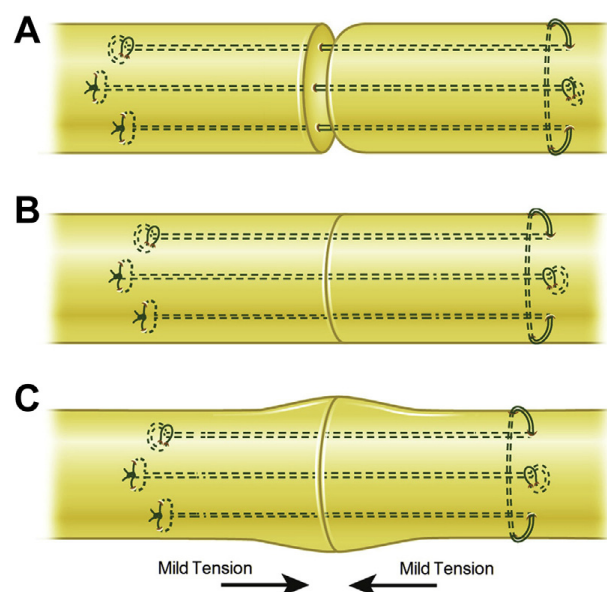


Fig. 7. The appropriate tensioning of the repair site is a key to preventing gap formation (A, B) during active finger flexion. The recommended degree of bunching up is 20% to 30% (shown in C) increases in diameter of the tendons at the junction of the 2 tendon ends.

Finally, at least a 4-strand core suture is required; a 6-strand core suture is ideal. The caliber of suture used in adults is either 4-0 or 3-0.

Locking suture-junction in the tendon is not a must, although locking anchors are slightly more secure. If the locks are incorporated, the locking circles of the suture in the tendon should be of a sufficient size (approximately 2 mm in diameter).

Peripheral sutures mainly serve to tidy up the repaired tendon stumps. Most surgeons now choose to insert only simple or sparse peripheral stitches. Some surgeons even do not supplement peripheral stitches when multistrand core sutures have been used.^{23,24} In the presence of a strong multistrand core repair that has been tensioned over the repair site, peripheral sutures become less important than previously thought.

I do not usually repair the flexor digitorum superficialis (FDS) tendon unless the FDS injury is partial or the wound is very clean. I do not repair the FDS tendon during delayed primary repair or if the injury is in the area of the A2 pulley (zone 2C).

Venting of the Critical Pulleys

It was previously believed that the A2 and A4 pulleys were sacrosanct and should not be divided. One of the important improvements in tendon repair in recent decades is the understanding that clinically significant bowstringing does not occur when the A2 pulley is released up to two-thirds of its length and that the A4 pulley can be entirely released, given the integrity of the other critical pulleys.^{13,15} A part of the synovial sheath including cruciate pulleys can be released together with the annular pulleys. The method of release is a longitudinal cut through the midline with a scissors.

However, no more than 1.5 to 2 cm total of the pulleys with the synovial sheath should be released.¹³ A pulley release does not need to be lengthy, because in the proximal part of a finger of an average adult, the flexor tendons glide only 1.5 to 2 cm with full digital extension and flexion. This judicious pulley venting permits unimpeded gliding of a strong but slightly bunched or edematous tendon repair site during early active tendon motion after surgery.

I have observed that judicious venting or division of the A4 pulley does not lead to clinically significant bowstringing, although anatomically there is minor tendon bowstringing that leads to no clinical consequence. The same is true of division of up to two-thirds of the A2 pulley.

Performing Digital Extension-Flexion Test: Methods

After repairing the tendon and venting of pulleys, I always verify the quality of the repair and adequate venting through a digital extension-flexion test.^{14,22} The repaired finger is held at full extension to confirm that no gaps are seen between the 2 cut ends. Next, the finger is moderately flexed to make sure the repaired tendon moves smoothly. Finally, the finger is further pushed to marked flexion to confirm that the repair site does not bunch against the pulleys and that venting of the pulley is adequate.

Under local anesthesia with sedation, brachial plexus blocks, or general anesthesia, the previously mentioned test is performed with the surgeon's hand holding the repaired finger to obtain passive finger motion. The wide-awake local anesthesia without a tourniquet approach offers a major advantage of the wide-awake surgery,²⁵ as the patient can actively move the tendon to ascertain repair quality.

If gapping is found between tendon ends, the repair is too loose and should be revised with additional core or peripheral sutures. If the pulley is found to block smooth tendon gliding, it should be further released. However, such additional release should be progressive, 1 to 2 mm at a time, with repeated digital extension-flexion tests, to ensure the release is just enough to let the repair site glide smoothly, rather than making 1 lengthy additional cut.

POSTOPERATIVE ACTIVE MOTION PROTOCOLS

I use a dorsal splint extending from the distal forearm to the fingertips for postoperative protection. Some other surgeons use an even shorter splint.¹⁶ The exact wrist position is unimportant. The wrist can be in neutral, mild flexion, or mild extension, as long as the patient is comfortable. The splint should be slightly flexed at the MCP joint, usually for 30° to 40°, and be straight beyond this joint. The wrist position for splinting should avoid marked flexion (which is uncomfortable) or marked extension (which adds a lot of tension to the repaired tendon).

There is no need to start motion or therapy in the first 3 or 4 days after surgery, which also avoids pain and discomfort.¹ From day 4 or 5, the patient should perform at least a few sessions of digital motion exercises. In each session, to lessen resistance of joint stiffness, full passive finger motion—usually 20 to 40 repetitions—should be performed

before active digital flexion. Then active digital flexion should proceed gradually. In the first 3 to 4 weeks, only one-half to two-thirds active motion range should be the goal. Extreme digital flexion should be avoided, because marked finger flexion would overload the repaired tendons, risking repair disruption (**Fig. 8**). Most patients have marked swelling at this time; a full range of active motion of the operated finger is difficult to achieve. Aiming for full active flexion of the finger is both unnecessary and unrealistic. However, full passive finger flexion and extension should always be performed to make the hand and finger as supple as possible.

From the end of week 3 or 4, a full range of active flexion is the goal. Some patients who have difficulty with full active flexion at week 4 or 5 may gradually achieve full flexion in later weeks. However, exercise to reduce joint stiffness and prevent extension lag should always be performed for eventual recovery of active finger flexion. The splint protection can be removed at the end of week 5 or 6, but therapy usually should persist for a few weeks to get rid of often seen remaining stiffness of the distal interphalangeal (DIP) joint, with or with nighttime splint protection. After week 6, I sometimes urge patients to wear a splint only when they go outside, which prevents unintentional use or injury.

MORE RECENT EVOLUTION OF METHODS

The major conceptual changes in repairing flexor tendons are summarized in **Table 2**. Although most of the advancements have already been discussed, here I summarize the changes over the last 5 to 6 years.

Placing the Knots Between the Two Tendon Ends May Not Favor the Repair

The modified Kessler repair was popular, but for zone 2 flexor tendon repair, this repair is now seldom used. It has also been realized that the original Kessler repair with knots over the tendon surface is actually slightly better than the modified version in terms of preventing gapping.²⁶ Most current multistrand repairs have knots over the tendon surface, and no adverse clinical consequences have been noted with these repairs (**Fig. 9**). It is now believed that placement of the knots between tendon ends is not beneficial or unimportant.²⁶⁻²⁸

Asymmetric Suture Configurations May be Preferable to Symmetric Designs

Recent investigations have revealed that asymmetry in the configuration of sutures attaching 2 tendon stumps is better than symmetric suture placement.^{29,30} Asymmetric placement likely

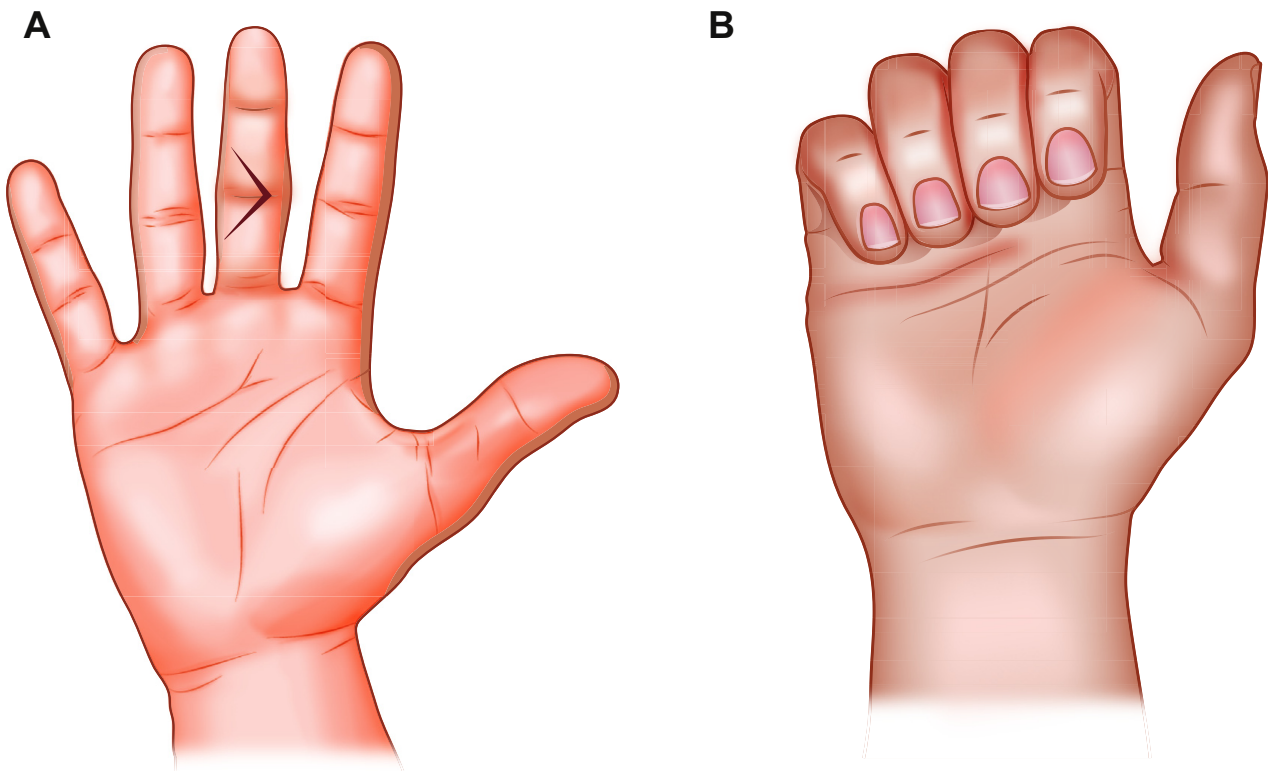


Fig. 8. Partial range active motion in the initial 2 to 3 weeks after surgery. Full fist or marked active finger flexion should be avoided to prevent repair rupture. (A) Active flexion starts from full extension. (B) Active flexion up to two-thirds of flexion arc is shown.

Table 2
The major conceptual changes in repairing flexor tendons over the past 3 decades

Subjects	1980s and 1990s	2010s
Surgical techniques		
Tendon repair: zone 2	2-strand suture	Multistrand suture (4 or 6 strands)
A2 pulley	Should not be violated	Can be partially vented if needed
A4 pulley	Should not be violated	Can be entirely vented if needed
Synovial sheath	Closure recommended	Do not need to repair the sheath
Suture purchase of repair	Not been stressed	Should be more than 0.7–1 cm
Tension across repair site	Not been discussed	An essential key of surgical repair
Extension-flexor test	None	A common quality check point
Wide-awake surgery	Not incorporated	A better approach of tendon repair
After surgery		
Wrist position in protection	Wrist flexion stressed	Flexible, from mild flexion to extension
Starting motion within 4 d	Common	Unnecessary; no motion is better
Active flexion: first 2–3 weeks	Not popular	Popular
Avoid extreme flexion	None	A key to ensure safety of active flexion
Place-and-hold motion	Popular	Not a useful or efficient exercise
Out-of-splint motion	None	Advocated for reliable patients

favors gap resistance, and this design can be found in some popular suture configurations.

A Tensioned Slightly Bunched Repair is Better Than a Flat Tension-Free Repair

A flat, tension-free repair should be avoided. A tensioned slightly bunched repair favors gap resistance and does not hamper tendon gliding as the narrow pulleys are released.

Slightly Extended Pulley Venting to Benefit Finger Flexion Outweighs the Drawbacks of Minor Tendon Bowstringing

The author and colleagues tend to be conservative in deciding the length of pulley release. The allowable length may be slightly longer than what was

proposed originally, in particular, if such a release greatly favors gliding of the repaired tendon, and the bowstringing caused by slightly extended release is noticeable but still mild. This practice appears especially beneficial at the PIP joint area. Such extended release from the A4 to A3 pulleys (including the sheath between them), if needed, may favor tendon gliding at the cost of mild bowstringing at the PIP joint, which actually does not affect normal function of the finger.^{23,24,31–34}

Peripheral Suture is Unnecessary When a Strong Core Suture (a 6-Strand Repair) is Used

This is a recent observation. A few surgeons have reported not adding peripheral sutures when a

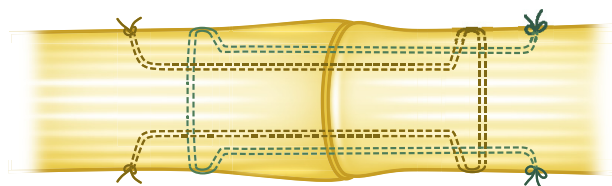


Fig. 9. A tendon repair showing most of the recognized points for making a reliable repair: sufficient lengths of suture purchase, no knots between the tendon ends, tension across repair site, slightly bunching up at the junction of the 2 tendon ends, and asymmetry of the suture strands in 2 tendon ends.

strong 6-strand repair is made with tension; no repair ruptures were reported.^{23,24}

Wide-Awake Surgery Allows Effective Testing of Tendon Gliding

This is a major development in flexor tendon repair. With active participation by the patient during surgery, the extension-flexion test provides the best validation of a successful repair. Surgeons can even educate the patient about postoperative motion during the procedure.³⁴⁻³⁷

Tendon-to-Bone Junction Can be Achieved Without Conventional Pull-Out Suture

As explained previously, a strong direct repair has replaced the pullout suture in my practice. The fact is that the terminal tendon just proximal to its insertion to the distal phalanx is distal to the DIP joint, which does not require motion. Adhesions are allowed to develop to help strengthen the repair. Therefore, as much as possible, suture strands can be used to achieve a strong and usually somewhat bulky repair, which favors both healing and strength.

Limiting the Length of Incision Decreases Gliding Resistance to the Tendon

A surgical incision less than 2 cm long is recommended to allow exploration of the wound site and expose the tendon in the finger or thumb. Such a short incision decreases postoperative edema and resistance to tendon gliding. Making a lengthy Bruner incision increases edema. If the tendon is retracted proximally to the palm, an additional incision is made, rather than extending the incision from the finger to the palm.

Wrist Positioning is Unimportant, and a Short Splint is Safe

It is now understood that if the tendon repair is strong, the wrist does not have to be placed in a specific position. This allows considerable freedom in wrist positioning.

Out-of-Splint Exercise is Safe

In my own practice, I have found out-of-splint motion to be safe for compliant patients; in fact, it is actually more efficient. Splinting mainly serves to protect the patient from getting hurt or unintentional hand use. For this reason, the splint should be worn only between exercise sessions and at night.

OUTCOMES

When they followed an updated protocol, young or junior hand surgeons were able to obtain reliably good outcomes with few or no repair ruptures.²² Surgeons from other units have reported zero ruptures in case series of more than 50 tendons.^{23,38,39} Repair rupture appears to no longer be a major concern if all modern guidelines are carefully followed. Rupture occurs only in patients who actively use the fingers in the first few weeks after surgery, although there are rare instances (estimated to be <1%) of unexplained ruptures of ordinarily reliable repairs.²² However, although cases of tenolysis have dropped considerably,⁴⁰ adhesions remain a concern, and severe tissue damage always poses the risk of developing dense adhesions.

REPAIR IN OTHER ZONES AND THUMB FLEXOR TENDONS

Zone 1

When the FDP tendon is cut in distal zone 1, pull-out sutures through the dorsal nail have been a common treatment, but I no longer use them. I prefer direct repair using several strong core sutures (ie, up to 10 or 12-strand core suture repair). The direct repair connects the proximal stump to the remnant of the distal stump and tissues such as periosteum adjacent to the tendon insertion on the distal phalanx (**Fig. 10**). The methods of proximal zone 1 repairs and zone 2 are similar.

Zones 3, 4, and 5

The FDP tendons in zone 3 are repaired similarly as in zone 2. The repairs are easier because of lack of sheath over the tendon. The injuries in the carpal tunnel area (zone 4) are rare and are often accompanied by lacerations in the median nerve and arteries. The transverse carpal ligament has to be opened to facilitate repairs. Zone 5 injuries often involve multiple tendons with neurovascular injury. Repair of the FDS and FDP tendons is preferred, and early postoperative motion is advised.

Thumb Flexor Tendon

The FPL tendon repairs follow the same methods of repairs of the FDP tendon in fingers. The surgical incision should usually be less than 2 cm. The oblique pulley has to be vented to allow performing the repair. I use the 6-strand M-Tang repair for all FPL tendons (**Fig. 11**).^{22,41} The proximal tendon frequently retracts into the thenar muscles, which can be retrieved through an incision in thenar muscles or the carpal tunnel.

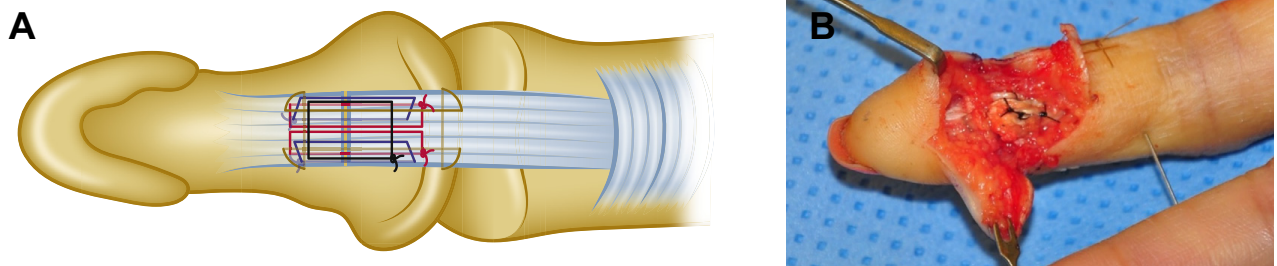


Fig. 10. (A) The method of a strong direct repair for repairing the tendon cut at or close to tendon-bone insertion of the finger. (B) An operative picture of this repair.

TENOLYSIS, PULLEYS, TENDON GRAFTING, AND STAGED RECONSTRUCTION

Tenolysis

It is estimated that about 10% to 20% of the patients still need tenolysis after primary or delayed primary repair. Tenolysis is best performed in a wide-awake setting without a tourniquet. The patient should move actively during the procedure to demonstrate ample active tendon motion. I perform wide-awake tenolysis whenever possible. The patient is asked to forcefully flex the finger and wrist to break any remaining adhesions after surgical release of adhesions.

Tendon Grafting and Staged Reconstruction

Although I follow established methods and principles for these procedures, I use direct repair of the grafted tendon to the residual stump of the distal FDP tendon when making a distal junction. For that purpose, I retain the distal stump for 1 cm (or slightly less) when removing the FDP tendons. Starting the end of week 1 after surgery, I instruct the patients to perform a full range of passive motion and less-aggressive active flexion of the finger that underwent surgery.

SUMMARY OF ADVANCEMENTS FOR ACHIEVING IDEAL REPAIR OUTCOMES

Zone 2 flexor tendon repairs have evolved greatly over the past 3 decades, including several key developments:

- Use of strong core sutures, typically 4- or 6-strand repairs
- Judicious venting of the critical annular pulley
- Ensuring that some tension is created by the repair to prevent gapping
- Performing digital extension-flexion tests to confirm the quality of the surgical repair
- Early partial-range active motion to ensure tendon gliding without overloading the repair

Direct repair of the terminal FDP tendon or in making the distal junction of the grafted tendon is my preference. A few recent changes reported by surgeons hold the promise of wider adoption:

- Using strong core-suture-only repair
- Venting the A3 together with A4 pulleys if greater range of motion of the finger is needed
- Using a wide-awake setting for tendon repair, including grafting

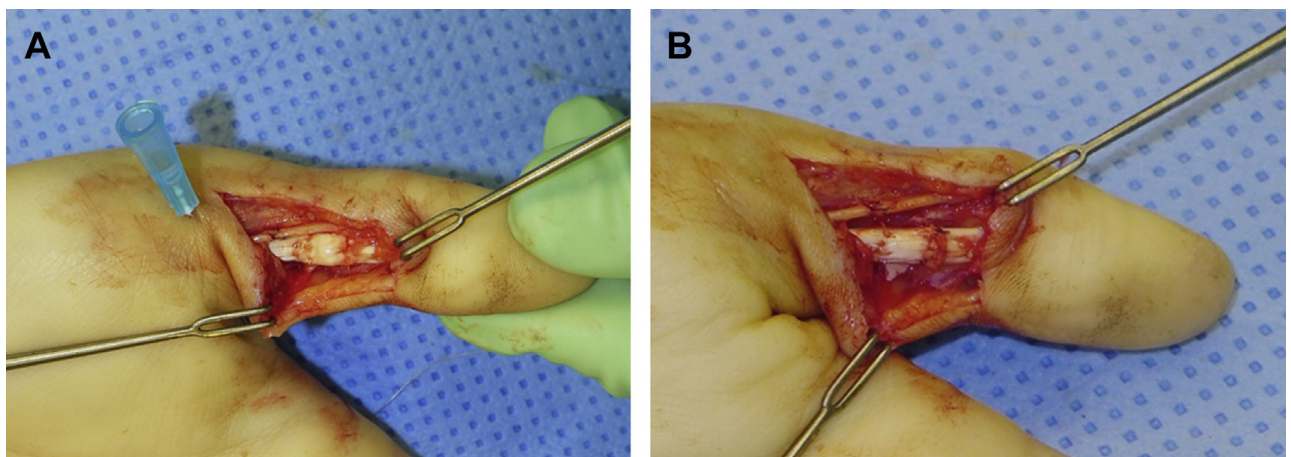


Fig. 11. The M-Tang repair for an FPL tendon cut. (A) After completion of repair, before taking the temporary needle fixation away, the tendon is seen slightly bunched up. (B) After the needle fixation is taken away, the tendon is flatter. No gapping was seen at thumb extension.

REFERENCES

1. Tang JB. New developments are improving flexor tendon repair. *Plast Reconstr Surg* 2018;141:1427–37.
2. Giesen T, Calcagni M, Elliot D. Primary flexor tendon repair with early active motion: experience in Europe. *Hand Clin* 2017;33:465–72.
3. Wong JK, Peck F. Improving results of flexor tendon repair and rehabilitation. *Plast Reconstr Surg* 2014;134:913e–25e.
4. Elliot D, Giesen T. Primary flexor tendon surgery: the search for a perfect result. *Hand Clin* 2013;29:191–206.
5. Tang JB. Recent evolutions in flexor tendon repairs and rehabilitation. *J Hand Surg Eur Vol* 2018;43:469–73.
6. Wu YF, Tang JB. Recent developments in flexor tendon repair techniques and factors influencing strength of the tendon repair. *J Hand Surg Eur Vol* 2014;39:6–19.
7. Wu YF, Tang JB. Effects of tension across the tendon repair site on tendon gap and ultimate strength. *J Hand Surg Am* 2012;37:906–12.
8. Savage R. In vitro studies of a new method of flexor tendon repair. *J Hand Surg Br* 1985;10:135–41.
9. Tang JB. The double sheath system and tendon gliding in zone 2C. *J Hand Surg Br* 1995;20:281–5.
10. Lalonde DH. Conceptual origins, current practice, and views of wide awake hand surgery. *J Hand Surg Eur Vol* 2017;42:886–95.
11. Lalonde DH, Martin AL. Wide-awake flexor tendon repair and early tendon mobilization in zones 1 and 2. *Hand Clin* 2013;29:207–13.
12. Tang JB. Clinical outcomes associated with flexor tendon repair. *Hand Clin* 2005;21:199–210.
13. Tang JB. Indications, methods, postoperative motion and outcome evaluation of primary flexor tendon repairs in Zone 2. *J Hand Surg Eur Vol* 2007;32:118–29.
14. Tang JB. Outcomes and evaluation of flexor tendon repair. *Hand Clin* 2013;29:251–9.
15. Kwai Ben I, Elliot D. “Venting” or partial lateral release of the A2 and A4 pulleys after repair of zone 2 flexor tendon injuries. *J Hand Surg Br* 1998;23:649–54.
16. Tang JB. Release of the A4 pulley to facilitate zone II flexor tendon repair. *J Hand Surg Am* 2014;39:2300–7.
17. Howell JW, Peck F. Rehabilitation of flexor and extensor tendon injuries in the hand: current updates. *Injury* 2013;44:397–402.
18. Tang JB, Xu Y, Wang B. Repair strength of tendons of varying gliding curvature: a study in a curvilinear model. *J Hand Surg Am* 2003;28:243–9.
19. Tang JB, Cao Y, Xie RG. Effects of tension direction on strength of tendon repair. *J Hand Surg Am* 2001;26:1105–10.
20. Wu YF, Tang JB. Tendon healing, edema, and resistance to flexor tendon gliding: clinical implications. *Hand Clin* 2013;29:167–78.
21. Tang JB, Amadio PC, Boyer MI, et al. Current practice of primary flexor tendon repair: a global view. *Hand Clin* 2013;29:179–89.
22. Tang JB, Zhou X, Pan ZJ, et al. Strong digital flexor tendon repair, extension-flexion test, and early active flexion: experience in 300 tendons. *Hand Clin* 2017;33:455–63.
23. Giesen T, Sirotakova M, Copsey AJ, et al. Flexor pollicis longus primary repair: further experience with the Tang technique and controlled active mobilization. *J Hand Surg Eur Vol* 2009;34:758–61.
24. Giesen T, Reissner L, Besmens I, et al. Flexor tendon repair in the hand with the M-Tang technique (without peripheral sutures), pulley division, and early active motion. *J Hand Surg Eur Vol* 2018;43:474–9.
25. Tang JB. Wide-awake primary flexor tendon repair, tenolysis and tendon transfer. *Clin Orthop Surg* 2015;7:275–81.
26. Chang MK, Wong YR, Tay SC. Biomechanical comparison of modified Lim/Tsai tendon repairs with intra- and extra-tendinous knots. *J Hand Surg Eur Vol* 2018;43:919–24.
27. Chang MK, Wong YR, Tay SC. Biomechanical comparison of the Lim/Tsai tendon repair with a modified method using a single looped suture. *J Hand Surg Eur Vol* 2017;42:915–9.
28. Chen J, Wu YF, Xing SG, et al. Suture knots between tendon stumps may not benefit tendon repairs. *J Hand Surg Eur Vol* 2018;43:1005–6.
29. Wu YF, Tang JB. The effect of asymmetric core suture purchase on gap resistance of tendon repair in linear cyclic loading. *J Hand Surg Am* 2014;39:910–8.
30. Kozono N, Okada T, Takeuchi N, et al. A biomechanical comparison between asymmetric Pennington technique and conventional core suture techniques: 6-strand flexor tendon repair. *J Hand Surg Am* 2018;43:79.e1–8.
31. Moriya K, Yoshizu T, Tsubokawa N, et al. Outcomes of release of the entire A4 pulley after flexor tendon repairs in zone 2A followed by early active mobilization. *J Hand Surg Eur Vol* 2016;41:400–5.
32. Moriya K, Yoshizu T, Tsubokawa N, et al. Clinical results of releasing the entire A2 pulley after flexor tendon repair in zone 2C. *J Hand Surg Eur Vol* 2016;41:822–8.
33. Moriya K, Yoshizu T, Tsubokawa N, et al. Outcomes of flexor tendon repairs in zone 2 subzones with early active mobilization. *J Hand Surg Eur Vol* 2017;42:896–902.
34. Reissner L, Zechmann-Mueller N, Klein HJ, et al. Sonographic study of repair, gapping and tendon bowstringing after primary flexor digitorum

- profundus repair in zone 2. *J Hand Surg Eur Vol* 2018;43:480–6.
35. Lalonde DH. Wide-awake flexor tendon repair. *Plast Reconstr Surg* 2009;123:623–5.
36. Higgins A, Lalonde DH, Bell M, et al. Avoiding flexor tendon repair rupture with intraoperative total active movement examination. *Plast Reconstr Surg* 2010;126:941–5.
37. Tang JB, Gong KT, Zhu L, et al. Performing hand surgery under local anesthesia without a tourniquet in China. *Hand Clin* 2017;33:415–24.
38. Zhou X, Li XR, Qing J, et al. Outcomes of the six-strand M-Tang repair for zone 2 primary flexor tendon repair in 54 fingers. *J Hand Surg Eur Vol* 2017;42:462–8.
39. Pan ZJ, Xu YF, Pan L, et al. Zone 2 flexor tendon repairs using a tensioned strong core suture, sparse peripheral stitches and early active motion: results in 60 fingers. *J Hand Surg Eur Vol* 2019;44:361–6.
40. Moriya K, Yoshizu T, Tsubokawa N, et al. Incidence of tenolysis and features of adhesions in the digital flexor tendons after multi-strand repair and early active motion. *J Hand Surg Eur Vol* 2019;44:354–60.
41. Pan ZJ, Qin J, Zhou X, et al. Robust thumb flexor tendon repairs with a six-strand M-Tang method, pulley venting, and early active motion. *J Hand Surg Eur Vol* 2017;42:909–14.