

# The Biomechanics of a Thumb Carpometacarpal Immobilization Splint: Design and Fitting

**Judy C. Colditz, OTR/L, CHT, FAOTA**

*Hand Therapy Consultant*

*HandLab (a division of RHRC, Inc.)*

*Raleigh, North Carolina*

**ABSTRACT:** Splinting for the common osteoarthritis of the carpometacarpal (CMC) joint of the thumb is infrequently described in the literature, but the few splints that are described include one or both adjacent joints. This paper describes the design and biomechanics of a custom-molded thumb CMC immobilization splint that excludes the thumb metacarpophalangeal and wrist joints. The problem of the imbalance of extrinsic extensor/abductor forces against the intrinsic flexor/adductor forces is described. The accompanying weakening of the thumb CMC capsule allows dorsal shifting of the proximal end of the metacarpal, producing pain. The splint described in this paper 1) prevents motion of the first metacarpal in relation to the other metacarpals, 2) prevents tilting (flexion) of the first metacarpal during pinch, and 3) allows unrestricted thumb metacarpal and wrist joint motion. Attention to detail during construction is required for an accurate pattern, precise positioning of the CMC joint during molding, accurate molding around the first metacarpal, and well-distributed pressure. This design may also be used for protection following thumb CMC arthroplasty or thumb CMC sprain or strain and as a base for thumb metacarpophalangeal and/or interphalangeal mobilization splinting.

J HAND THER. 13:228-235, 2000.

The thumb trapeziometacarpal joint, also called the thumb carpometacarpal (CMC) joint, is the most common site in the upper extremity for surgery due to disabling osteoarthritis.<sup>1</sup> Osteoarthritis of the thumb CMC joint is particularly prevalent in postmenopausal women,<sup>2,3</sup> many of whom already have normal laxity of this joint.<sup>1</sup> Osteoarthritis causes increased laxity of the thumb CMC joint capsule, creating a common clinical complaint of pain with resisted thumb motion, particularly forceful pinching.

Most surgeons and therapists writing about treatment of the painful thumb CMC joint use immobilization splinting as a part of conservative treatment. Only one recent article looks at the effectiveness of thumb CMC immobilization splinting.<sup>4</sup> Descriptions of the

splint designs recommended as part of the nonsurgical treatment, if included at all, are usually vague.<sup>3,5-7</sup> The few splints that are illustrated or specifically described usually include one or both adjacent joints.<sup>1,4,8</sup>

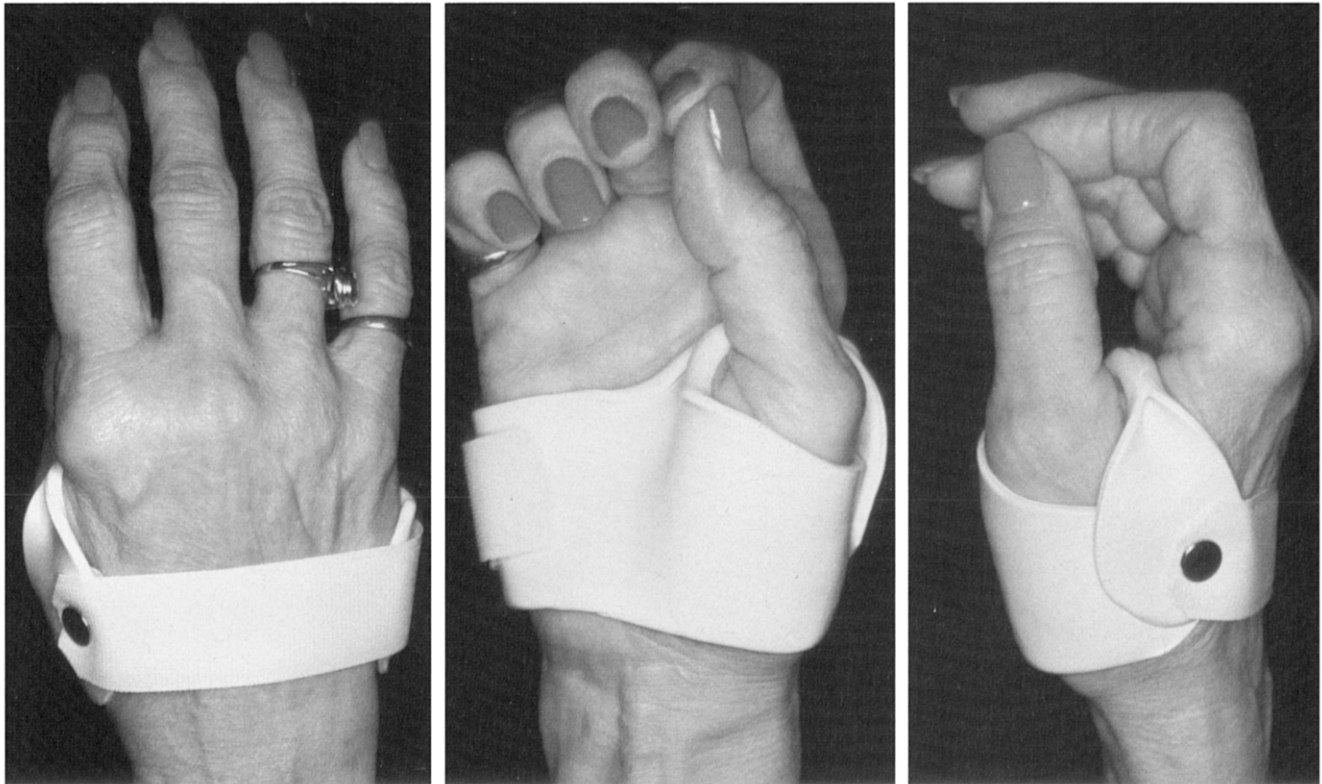
Poor patient compliance and limitation of hand function in the splint are listed as detriments to thumb CMC joint immobilization splinting.<sup>1,6,7,9,10</sup> It is assumed that authors are using splints that include at least one and often both adjacent joints. Therefore, the reason for poor compliance and limited hand function may be related to the number of immobilized joints.

Immobilization of the thumb metacarpophalangeal joint robs the hand of the valuable flexion, extension, and radial and ulnar deviation of that joint. Immobilization of the wrist demands greater range of proximal joints, making function more demanding. The choice for the patient is often compliance with immobilization vs. functional use.

This paper describes the design and biomechanics of a custom-molded thermoplastic splint that leaves the

This paper was presented at the 22nd Annual Meeting of the ASHT, on September 17, 1999, in Orlando, Florida.

Correspondence and reprint requests to Judy C. Colditz, OTR/L, CHT, FAOTA, Hand Therapy Consultant, HandLab, 2615 London Drive, Raleigh, NC 27608; e-mail: <jccolditz@aol.com>.



**FIGURE 1.** Dorsal (left), palmar (middle), and radial (right) views of small thumb CMC immobilization splint made of 1/8-inch-thick thermoplastic splinting material.

thumb metacarpophalangeal and wrist joints unrestricted (Figure 1). The only limitation of function with this splint is when a flat palm is needed (as in pushing up off the floor with the palm, wiping a flat surface, or carrying a tray overhead). With this small splint patients report absent or diminished pain with resisted thumb motions. Since the splint does not impede other joint function, this design may provide an effective alternative to larger, more restrictive splints, thereby increasing compliance.

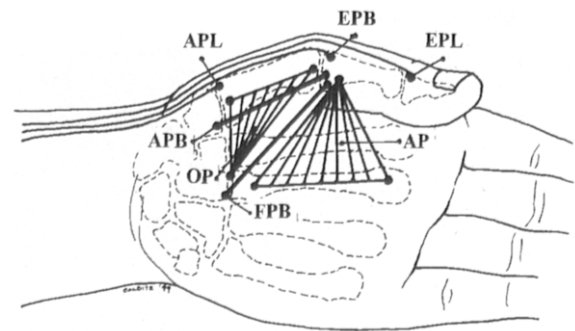
This small splint has previously been illustrated in the literature,<sup>11</sup> but its pattern, biomechanics, and construction methods have not been described. Although many experienced clinicians contend that a splint must cross the wrist to adequately stabilize the CMC joint, the author's experience is that patients with isolated CMC arthritis (who have no associated scaphotrapezium arthritis) receive symptomatic relief with this splint.

## PRINCIPLES

It is the author's hypothesis that the muscles crossing the joint create an imbalance of forces as the weaker dorsal portion of the thumb CMC capsule allows excessive motion. The splint is designed to prevent the motion that is hypothesized to create pain during pinch.

There are four intrinsic thenar muscles: the adductor pollicis (AP), the flexor pollicis brevis (FPB), the

opponens pollicis (OP), and the abductor pollicis brevis (APB) (Figure 2). The FPB flexes the first metacarpal across the palm, and the APB pulls the metacarpal into palmar abduction. The OP and the AP are larger than the FPB and APB, with the OP inserting along the length of the first metacarpal and the AP originating along the length of the third metacarpal. The AP brings the first metacarpal toward the second metacarpal. The OP rotates the first metacarpal as the entire thumb reaches toward a fingertip.<sup>12</sup> All these muscles contract to stabilize the thumb CMC and metacarpophalangeal joints



**FIGURE 2.** Schematic drawing showing the efficient line of pull of the thenar muscles compared with the less efficient line of pull of the extrinsic extensor and abductor muscles. APB indicates abductor pollicis brevis; EPB, extensor pollicis brevis; EPL, extensor pollicis longus; APB, abductor pollicis brevis; OP, opponens pollicis; FPB, flexor pollicis brevis; AP, adductor pollicis.

during pinch so that the force of the flexor pollicis longus can be transmitted distally. Because the insertion of the AP, FPB, and APB are distal to the thumb metacarpophalangeal joint, these muscles have a long moment arm to effect CMC joint motion. In addition, the long insertion of the OP on the first metacarpal allows this muscle to effectively move the CMC joint.

The antagonist muscles, however, are extrinsic muscles with weaker mechanical advantage (Figure 2). Originating on the radius and the ulna in the forearm, the abductor pollicis longus (APL) inserts on the base of the first metacarpal. Because the tendon insertion is close to the axis of the joint, it provides little mechanical advantage for extension at the CMC joint.

The extensor pollicis brevis (EPB) originates on the interosseus membrane and the radius in the forearm and inserts just beyond the thumb metacarpophalangeal joint into the base of the thumb proximal phalanx. It primarily extends the thumb metacarpophalangeal joint and secondarily extends/abducts the thumb CMC joint. Only when the metacarpophalangeal joint of the thumb is fully extended does it then effectively act on the CMC joint. The extensor pollicis longus (EPL) originates in the forearm from the interosseus membrane and the ulna, inserting at the base of the distal phalanx. Crossing over all three thumb joints, the EPL can assist in CMC joint extension only after it has exhausted its excursion at the other joints.

Therefore, the APL, EPB, and EPL muscles are relatively inefficient extensors and abductors at the CMC joint, in contrast to the more efficient intrinsic thenar muscles that primarily flex and adduct/abduct the thumb CMC joint. With three of the four thenar muscles (the FPB, OP, and AP) pulling the first metacarpal head toward the palm (into flexion), the balance of motion at the thumb CMC appears to the author to be loaded toward flexion (Figure 2).

As osteoarthritis develops, the already slack cap-

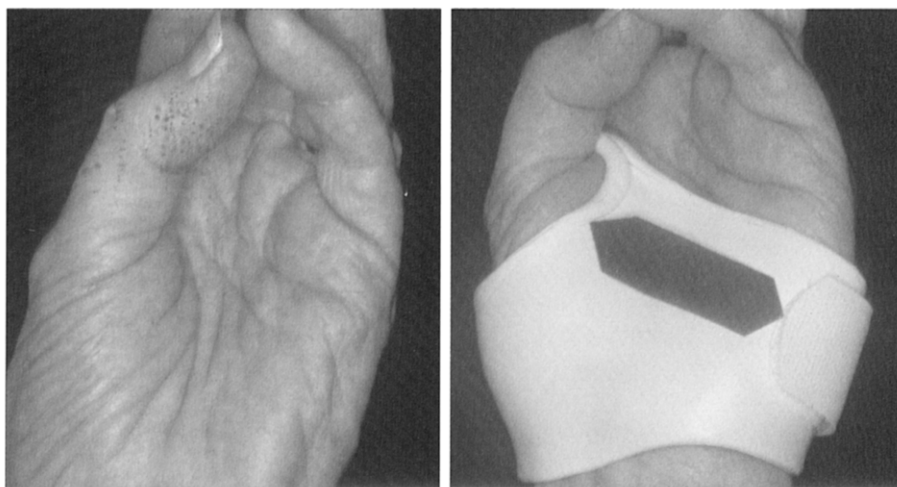
sule of the thumb CMC joint becomes attenuated. Pellegrini<sup>1</sup> describes the shift of the distal attachment of the stabilizing volar beak ligament distally on the metacarpal as eburnation of the articular surfaces progresses. He states: "This shift...compromise[s] the beak ligament's] mechanical efficiency in checking dorsal migration of the metacarpal on [the] trapezium during dynamic flexion-adduction of the thumb." The weaker dorsal fibers of the trapeziometacarpal capsule allow the base of the first metacarpal to sublux dorsally. As the intrinsic thenar muscles pull on the distal end of the first metacarpal, it flexes forward, levering the metacarpal. Therefore it is postulated that during pinch, when the thenar muscles contract, the first metacarpal tilts; i.e., the distal end moves toward the palm and the proximal end shifts dorsally. It is this shift of motion, although perhaps slight, that appears to create pain. This splint appears to prevent the first metacarpal tilting motion, controlling pain during thumb use.

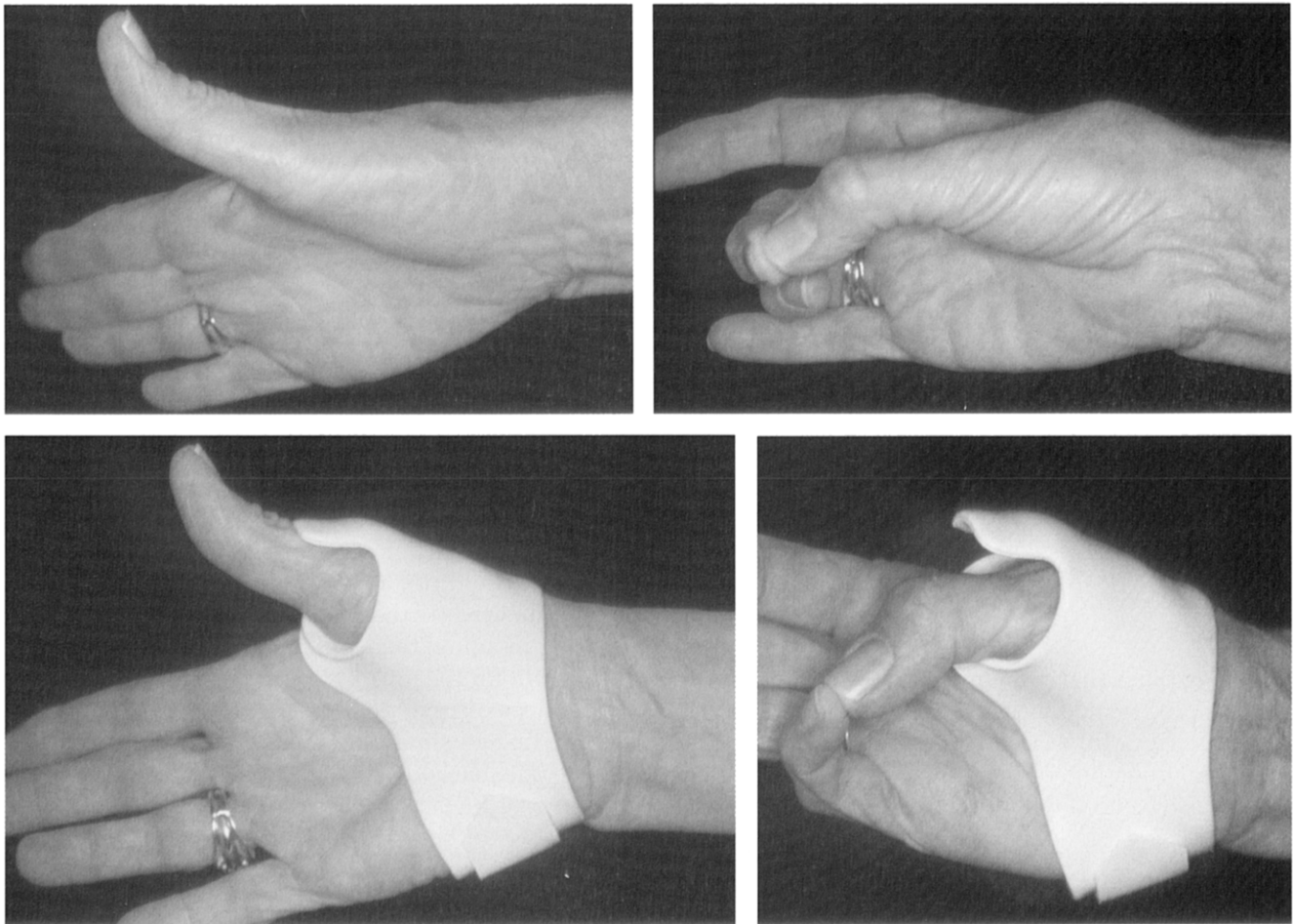
## RATIONALE

### Immobilization of the Thumb Metacarpotrapezial Joint

Splints that immobilize the thumb metacarpophalangeal or the wrist joint (or both) in addition to the thumb CMC joint effectively eliminate pain at the thumb CMC joint.<sup>1,4</sup> The difficulty in effectively immobilizing the first metacarpal without including other joints is the inability to mold splinting material circumferentially around the first metacarpal. This design uses the stability of the adjacent immobile second and third metacarpals as the anchor for the first metacarpal. In other words, motion of the first metacarpal in relation to the other metacarpals is prevented. The thumb CMC joint is stabilized in a position of palmar abduction so that fingertip and lateral pinch is unimpeded.

**FIGURE 3.** Left, During opposition, the distal end of the first metacarpal flexes toward the fifth metacarpal. Right, With the thumb CMC immobilization splint in place, the first metacarpal is stabilized and flexion occurs at the distal joints.





**FIGURE 4.** Patient with dorsally subluxed thumb CMC joint shows thumb metacarpophalangeal hyperextension during attempted thumb extension (top left) and lack of thumb metacarpophalangeal flexion during active flexion (top right). The small CMC immobilization splint with a dorsal block changes the pattern of motion by preventing hyperextension of the metacarpophalangeal joint during extension of the thumb (bottom left) and blocking thumb CMC flexion (bottom right), thereby demanding more motion at the thumb interphalangeal and metacarpophalangeal joints.

### Prevention of First Metacarpal Tilting

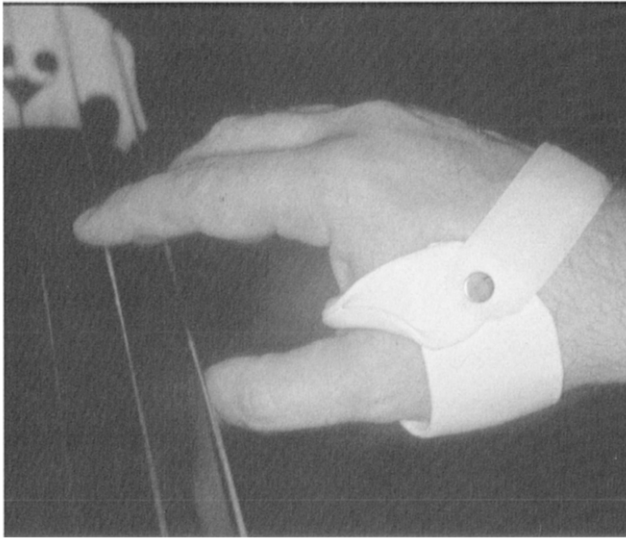
The rigid splint material molded across the palm creates a strut. This strut prevents the distal end of the metacarpal from tilting toward the ulnar border of the hand during pinch (Figure 3). Motion of the CMC joint is blocked, and the flexion force can only be transmitted more distally across the metacarpophalangeal and interphalangeal joints. The strut is effective because of thenar muscle contraction. With the rigid splinting material in the palm, the thenar muscles cannot expand out toward the environment as they contract. Their expansion force is directed backward toward the first metacarpal, stabilizing it. This muscle contraction supports the distal end of the metacarpal from flexing forward. This pseudo-hydraulic environment of muscle contraction within a closed space is recognized as the primary principle behind long bone fracture stabilization with functional fracture braces.<sup>13-16</sup>

As the thumb CMC joint subluxes dorsally, the mechanics of the thumb are altered, changing the balance of forces that cross the thumb metacarpophala-

ngeal joint. A modified pull on the thumb metacarpophalangeal joint creates secondary problems of imbalance at this joint.<sup>3</sup> Subluxation of the thumb CMC joint may lead to secondary radial deviation deformity of the thumb metacarpophalangeal joint due to an adduction contracture of the first metacarpal. Alternatively, a hyperextension deformity of the thumb metacarpophalangeal joint may develop as the flexion/adduction of the first metacarpal<sup>17</sup> allows a straighter line of pull of the extensor pollicis brevis and extensor pollicis longus (see Figure 2 and Figure 4, top left).

Early stabilization of the thumb CMC joint with the small CMC immobilization splint allows maintenance of the normal mechanics across the metacarpophalangeal joint. If the imbalance has already begun, an extension of the CMC splint dorsally over the thumb metacarpophalangeal joint to block it in mild flexion can alter the pattern of motion during pinch, slowing a further progression of this deformity (Figure 4).

One criticism is that this design deprives the palm of tactile input. It is the activities of daily living



**FIGURE 5.** The small thumb CMC immobilization splint does not impede fingering or pinching activities, such as playing a stringed instrument.

requiring pinch that primarily cause symptoms at the thumb CMC joint.<sup>1</sup> Since this splint leaves the critical digital sensory input unimpeded, it does not impair pinching, fingering, or handling activities (Figure 5). It may also be used without impairing most gripping activities.

## OBSERVATIONS

The smaller any splint, the more difficult it is to make accurately. This small and seemingly simple splint requires finesse and attention to detail to be successful in controlling thumb CMC pain. Not all patients can be helped with this CMC splint, but to maximize the probability of symptom reduction, attention to detail in construction of this splint is necessary. The successful stabilization of the thumb CMC joint with this splint design is dependent on 1) an accurate pattern, 2) precise positioning of the CMC joint during molding, 3) accurate molding to support the first metacarpal out of a position of flexion at the distal end, and 4) attention to detail so that pressure is well distributed.

### Accurate Pattern

To effectively immobilize the first metacarpal in a position of palmar abduction, the splint pattern must accommodate the first metacarpal position. In palmar abduction, the metacarpal lies in a plane at a 90° angle to the plane of the palm (the plane of the stable second and third metacarpals.) It is the angle of the large flange of the Y-shaped pattern<sup>†</sup> that allows pre-

cise molding around the first metacarpal in palmar abduction (Figure 6). When therapists are taught this design, the flanges are frequently drawn with undesirable angles in the initial pattern. This results in difficulty with proper positioning of the first metacarpal, and the splint then does not provide adequate support.

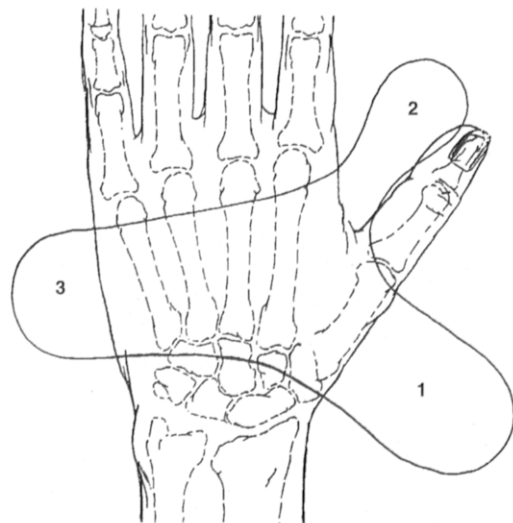
### Precise Positioning of the CMC Joint During Molding

After the pattern is drawn and traced on the thermoplastic material, the material is heated and cut. While the patient's elbow is stabilized on a work surface, the patient is instructed to touch the tip of the thumb to the tip of the index finger in a relaxed position. This position will ensure that the patient can comfortably reach the fingertips with the thumb. The patient should not actively pinch while the splint is being molded. If the thenar muscles are contracted during molding, there will be too much space inside the splint for the muscles to successfully stabilize the metacarpal during pinch.

The fingers should be relaxed in flexion with the wrist in extension. This position creates the natural transverse metacarpal arch that should be incorporated into the splint.

### Accurate Molding to Support the First Metacarpal

As the thermoplastic material is cooling and becoming firm, gentle pressure to mold the splint should be applied over the thenar muscles palmarly and over the proximal end of the first metacarpal



**FIGURE 6.** The pattern for the thumb CMC splint is Y-shaped. Flange 1 is angled and wraps around the first metacarpal when it is in a position of palmar abduction. The throat of flange 2 is rolled prior to placing it through the thumb web space. Flange 3 wraps around the ulnar border of the hand.

<sup>†</sup>This CMC pattern is available in pre-cut, sized thermoplastic splinting kits from North Coast Medical, Inc., Morgan Hill, California.

dorsoradially (Figure 7). The therapist must actually compress the thenar muscles slightly with the splinting material, with specific molding distally on the palmar piece to prevent the first metacarpal from tilting forward. Care must be taken not to push the metacarpal into so much extension that fingertip pinch becomes difficult or impossible. Attention must also be given to ensuring that the palmar edge of the splint is well below the thumb metacarpophalangeal joint, allowing full metacarpophalangeal flexion. The therapist must be observant, to make the splint long enough that it stabilizes the distal end of the metacarpal but not so long that it impedes thumb metacarpophalangeal flexion.

Pressure over the proximal end of the dorsoradial aspect of the first metacarpal should be minimal. The goal is to conform the splinting material snugly around the entire thumb base, not to apply force to attempt reduction of the dorsally subluxed metacarpal base. It appears to be the prevention of motion at this joint during pinch that reduces pain, not the ability of the splint to reduce the subluxation. Pressure that attempts to reduce the joint can actually exacerbate the pain.<sup>3</sup>

Even patients with grossly dislocated CMC joints can receive benefit from this CMC immobilization splint, because it is the elimination of motion at this joint and not the alignment of the joint that reduces pain. Although such an application of a splint would not in any way remediate the problem, the support the splint provides during thumb use has consistently been reported by patients to reduce pain.

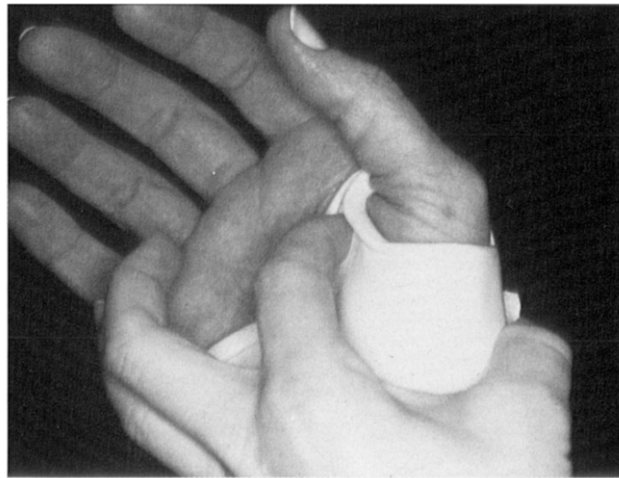After molding, the strap is attached with a rapid rivet on the overlapping flanges on the dorsoradial aspect of the splint. The rivet serves to hold the two overlapped flanges securely together. If a rivet is not used for the strap attachment, the therapist should bond these two flanges together before applying a strap.

When the completed splint is applied, the patient should be instructed to push the splint down fully on the thumb so that it is seated over the thenar area with full contact. Splints that are quickly applied without this downward pressure may be loose and may provide inadequate stabilization even with precision molding.

### Distribution of Pressure Areas

There are three areas in which care must be taken during molding, so that the splint fits comfortably: the dorsoradial aspect of the base of the first metacarpal, the first web space, and over the dorsum of the second metacarpal.

When the splint is molded and counter-pressure to the dorsoradial aspect of the CMC joint is applied, care must be taken so that the edge of the splint does not press on the area (see Figure 1, *middle* and *right*). This area is often enlarged, with underlying osteophytes,



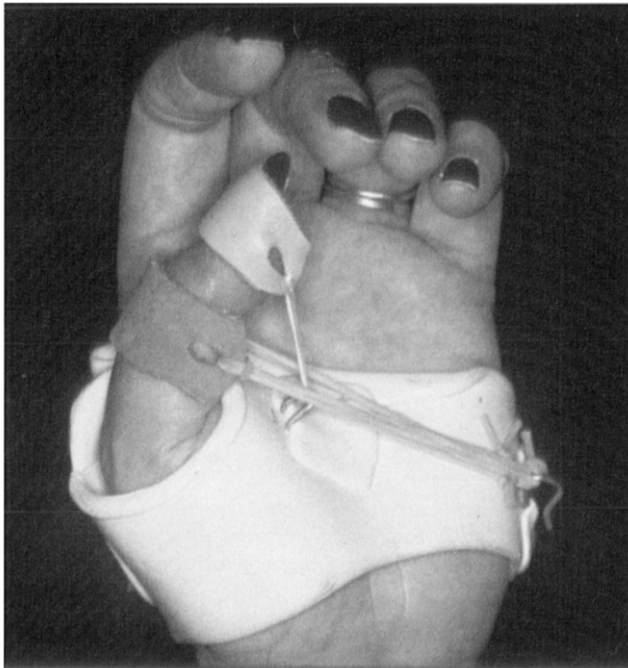**FIGURE 7.** Gentle pressure is applied over the distal end of the first metacarpal palmarly and over the proximal end of the metacarpal dorsoradially as the thermoplastic material hardens.

and pressure from the splint edge may be uncomfortable. There is a fine line between the splint being long enough to cover the metacarpal length and yet short enough to allow unimpeded wrist motion.

If the base of the metacarpal is dorsally subluxed or dislocated significantly, the bony prominence of the base may poorly tolerate pressure. At times, gel padding may be needed if counter-pressure over this area is to be tolerated. Patients often state that they feel the splint should cover the entire radial aspect of the wrist, since there is referred pain proximal to the thumb CMC joint. Even though patients often request that the splint extend over the radial aspect of the wrist, it is the author's experience that the shorter design adequately alleviates symptoms.

If the splint is pulled tightly through the first web space during molding, radial deviation of the thumb metacarpophalangeal joint and extension of the index finger will cause the web skin to rub against the splint, and comfortable wear of the splint is diminished. Prior to application of the warm splinting material, the web area of the splint should be rolled to form a circle (see Figure 1, *right*, and flange 2 on Figure 6). Rolling strengthens this part of the splint while minimizing bulk in the first web space. While the patient holds the index and thumb fingertips touching (without pinching), the splint material is gently brought through the first web. As the material begins to harden, the curled material is lifted away from the first web skin so that the material and skin do not touch. The first web skin should not rub against the splint when the patient holds a large object with full extension and radial deviation of the thumb metacarpophalangeal joint.

The ulnar border of the splint ends just as the splinting material begins to wrap dorsally (see Figure 1, *left*). Pressure is well distributed over the abductor digiti quinti muscle belly. If the ulnar border extends too far dorsally, application and removal of the splint



**FIGURE 8.** The CMC immobilization splint serves as an effective base to stabilize the first metacarpal when force is being applied to more distal joints. In this example, concurrent force to flex the metacarpophalangeal and interphalangeal joints of the thumb is applied to increase distal excursion of the extensor pollicis longus, which is adherent over the first metacarpal where it was lacerated.

can be both painful and difficult for the patient.

On the radial border of the splint dorsally (Figure 1, left and right), the dorsal edge of the splint ends just before the second metacarpal. There is little subcutaneous tissue padding in this area, and as the strap is pulled firmly across the dorsum of the hand the radial edge may press on the second metacarpal, causing exquisite pain. Attention to this potential problem can prevent unnecessary discomfort and increase compliance.

On completion of the splint, ask the patient to pinch both with and without the splint on. If the patient cannot immediately appreciate a reduction of pain with pinch with the splint on, the splint should be remolded to better stabilize the first metacarpal.

Patients who have just received an injection in the thumb CMC joint will not be able to provide this feedback, and the temporary enlargement of the joint from the injection will cause the splint to fit poorly in a few days. In such cases fitting of the splint should be delayed for a few days or the patient scheduled to return for remolding of the splint.

### Material Recommendation

Thermoplastic splinting materials with memory require constant pressure to ensure a conforming fit while the material cools. Because there are numerous small areas of this splint that require precise posi-

tioning simultaneously, it is recommended that materials with a strong memory be avoided. The constant pushing necessary for molding these materials prevents the accuracy of definitive molding. It is also questionable whether splints made of thermoplastic splinting material thinner than 1/8 inch provide adequate stabilization.

### Recommended Wear

There is little information in the literature regarding suggested wearing schedules for CMC immobilization splints to reduce painful symptoms of osteoarthritis. When included, instructions for wear vary from continuous wear for three to four weeks<sup>4</sup> to intermittent wear when the joint is painful.<sup>5</sup>

Many patients present for medical intervention following an episode of overuse that has caused the trapeziometacarpal joint to become inflamed. The small splint described here should initially be worn full-time for a period of two to three weeks (with removal for skin care only). Following this period of full-time immobilization, the splint is worn to prevent irritation of the joint with repetitive thumb use or to reduce symptoms after such irritation has occurred. Most patients choose to wear the splint routinely at night and are encouraged to do so. The most important time to wear the splint is during activities that cause pain at the CMC joint, and patients are instructed to do so.

Numerous patients have elected to use the splint in this manner over a number of years to control symptoms rather than undergo an arthroplasty procedure. Unlike most splints applied to joints, this CMC splint cannot be worn too long or too much. The problem at the thumb CMC joint is one of excessive motion. It would be ideal if the splint were worn enough for the joint to "stiffen" and have greater stability.

A patient will eagerly wear the splint only if it is molded correctly, with attention to detail for precise support and positioning and avoidance of painful pressure areas. When the splint is correctly molded, patients report an immediate elimination or reduction of thumb CMC pain with pinch.

### Use of this Design Following Thumb CMC Arthroplasty, Sprain, or Strain

The small splint design described here may be fitted to patients who have had CMC arthroplasty, after the initial immobilization has been discontinued and edema has subsided. This splint allows the patient functional use of the thumb while protecting the healing thumb CMC capsule. Since the patient contracts the thenar muscles in the splint during pinch with the CMC joint in a desirable position, this splint prepares the patient for effective weaning from external support. For patients who sustain a sprain or strain injury to the

thumb CMC joint, this small splint allows continuing use of the hand while protecting the healing capsule.

### Use as a Base Design for Other Thumb Problems

The CMC immobilization design is useful to stabilize the first metacarpal while immobilizing the thumb metacarpophalangeal joint, or while mobilizing the thumb metacarpophalangeal and/or interphalangeal joints. To immobilize or restrict thumb metacarpophalangeal motion following ligamentous injuries, the pattern can be extended to include the metacarpophalangeal joint. This makes a removable thumb metacarpophalangeal immobilization splint that protects the thumb metacarpophalangeal from external force without including the wrist joint. Outriggers may be added to the CMC immobilization splint to provide a pull to either the thumb metacarpophalangeal and/or interphalangeal joint (Figure 8). Since the base design adequately stabilizes the first metacarpal, the force of the pull is efficiently directed to the more distal joints.

### CONCLUSION

This splint design has been used for more than 20 years with isolated trapeziometacarpal arthritis. Many patients have returned for replacement splints as old splints have become brittle and have broken. It appears that thumb CMC pain can successfully be controlled without including other joints, if care is taken with positioning and molding. Immediate reduction or elimination of pain with pinch must be reported by the patient to ensure that the splint has been molded correctly. If remolding of the splint cannot achieve reduction or elimination of pain with pinch, inclusion of either the thumb metacarpophalangeal joint or the wrist, or both, may be necessary to control symptoms.

With splinting being recognized as part of routine initial care for the frequently occurring thumb CMC osteoarthritis, hand therapists are often required to construct custom-made thumb CMC immobilization splints. This small splint, designed by the author, can be completed in 15 minutes or less by a therapist experienced in its design and fitting. Because the

small size of the splint allows unrestricted use of adjacent joints, it is a cost-effective, efficient treatment option for those patients who elect to postpone or exclude surgical reconstruction for thumb CMC joint pain.

### REFERENCES

1. Pellegrini VDJ. Osteoarthritis at the base of the thumb. *Orthop Clin North Am.* 1992; 23:83-102.
2. Armstrong A, Hunter JD. The prevalence of degenerative arthritis of the base of the thumb in postmenopausal women. *J Hand Surg.* 1994; 24A:340-1.
3. Eaton RG, Glickel SZ. Trapeziometacarpal osteoarthritis: staging as a rationale for treatment. *Hand Clin.* 1987; 3:455-71.
4. Swigart C, Eaton R, Glickel S, Johnson C. Splinting in the treatment of arthritis of the first carpometacarpal joint. *J Hand Surg.* 1999; 24A:86-91.
5. Dell PC, Brushart TM, Smith RJ. Treatment of trapeziometacarpal arthritis: results of resection arthroplasty. *J Hand Surg.* 1978; 3:243-9.
6. Eaton RG, Littler JW. Ligament reconstruction for the painful thumb carpometacarpal joint. *J Bone Joint Surg.* 1973;55A: 1655-66.
7. Pellegrini VDJ. The basal articulations of the thumb: pain, instability, and osteoarthritis. In: Peimer CA (ed). *Surgery of the Hand and Upper Extremity.* New York: McGraw-Hill, 1996:1019-42.
8. Melvin JL. *Rheumatic Disease: Occupational Therapy and Rehabilitation.* 2nd ed. Philadelphia: F.A. Davis, 1982.
9. Burton RI. Basal joint arthrosis of the thumb. *Orthop Clin North Am.* 1973; 4:347-8.
10. Lane L, Eaton R. Ligament reconstruction for the painful "prearthritic" thumb carpometacarpal joint. *Clin Orthop Rel Res.* 1987; 220:52-7.
11. Colditz JC. Anatomic considerations for splinting the thumb. In: Hunter JM, Mackin EJ, Callahan AD (eds). *Rehabilitation of the Hand.* 4th ed. St. Louis, Mo: Mosby, 1995:1161-72.
12. Kendall F. *Muscles: Testing and Function with Posture and Pain.* 4th ed. Baltimore, Md: Williams & Wilkins, 1993.
13. Bunch WH, Keagy RD. *Principles of Orthotic Treatment.* St. Louis, Mo: Mosby, 1976.
14. Latta LL, Sarmiento A, Tarr RR. The rationale of functional bracing of fractures. *Clin Orthop Rel Res.* 1980; 146:28-36.
15. Sarmiento A. Functional fracture bracing: an update. *American Academy of Orthopaedic Surgeons Instructional Course Lectures.* 1987:371-6.
16. Zagorski JB, Zych GA, Latta LL, McCollough NC. Modern concepts in functional fracture bracing: the upper limb. *American Academy of Orthopaedic Surgeons Instructional Course Lectures.* 1987:377-401.
17. Terrono AL, Nalebuff EA, Philips CA. The rheumatoid thumb. In: Hunter JM, Mackin EJ, Callahan AD (eds). *Rehabilitation of the Hand.* 4th ed. St. Louis, Mo: Mosby, 1995:1329-43.